Uterus transplantation with live donors: outcome of the first clinical trial

Randa Akouri MD, PhD

Obstetrics and Gynecology, University of Gothenburg

Bridging reproductive medicine and gyne-oncology surgery

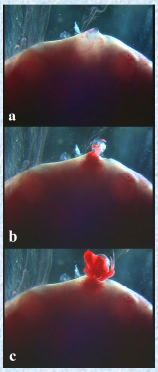

Patient-initiated research

1998, Royal Adelaide Hospital, Australia

- Angela 27 years
- cervical cancer st 1b
- radical hysterectomy with preservation of ovaries
- UTx? - mother donor???

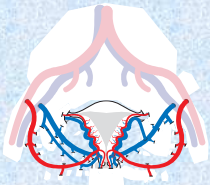

Absolute Uterine Factor Infertility (AUFI)

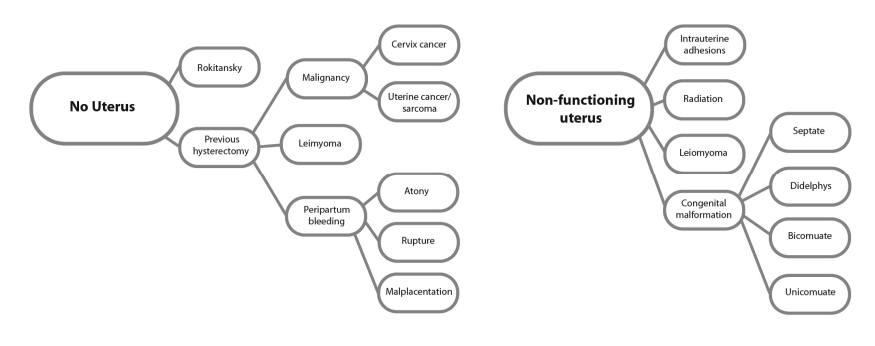

≈200,000 AUFI patients in Europe

(Sieunarine et al, Int Surg, 2005)

Motherhood options: adoption, gestational surrogacy

First two human UTx attempts

- Jeddah, Saudi Arabia, 2000
- 46-years live donor to 26-years hysterectomized (EPH)
- questionable whether properly perfused
- necrotic uterus removed after 3 months
- failure
- no preparatory research studies on UTx


International Journal of GYNECOLOGY & OBSTETRICS

International Journal of Gynecology & Obstetrics 76 (2002) 245–251

www.elsevier.com/locate/ijgo

Case report

Transplantation of the human uterus

W. Fageeh*, H. Raffa, H. Jabbad, A. Marzouki

Multiorgan Transplant Unit, King Fahad Hospital and Research Center, Jeddah, Saudi Arabia

- Antalya, Turkey, 2011
- deceased (heart-beating brain-dead) donor (23-year old) to 21-year old Rokitansky patient

FIGO; Ethical guidelines- Uterine transplantation

- -uterine transplantation, which may reach clinical experimental stage, should only occur after significant and adequate research in appropriate large animal models, including primates
- the lengths to which some women will go to experience uterine transplantation, even with the availability of such options as adoption and surrogacy in some cultures, can lead to a conflict of interest and pressure on researchers to move prematurely to human application
- it is unethical to remove a uterus for transplantation from a young woman who did not complete having the desired number of children
- given the lack of data on safety and the known hazards to live donors, the procedure is considered ethically inappropriate

(Int J Gyn Obstet 2009;106:270)

Translational research

- Animal research (1999-2012)
  - Mouse
  - Rat
  - Pig
  - Sheep
  - Baboon
- Clinical trial (2013-)
- First livebirths (2014)

- Mouse/rat from 1999
  - Rache El-Akouri et al J Endocr 2002
  - Rache El-Akouri et al Hum Reprod 2003a.
  - Rache El-Akouri et al Hum Reprod2003b
  - Rache El-Akouri et al Hum Reprod 2006
  - Wranning et al Hum Reprod 2007
  - Wranning et al Acta Obstet Gynecol 2008
  - Groth et al Hum Reprod 2009
  - Groth et al Hum Reprod 2010
  - Wranning et al Hum Reprod 2011
  - Diaz-Garcia et al Acta Obstet Gynecol 2010
  - Akin et al Fertil Steril 2012
  - Groth et al J Obstet Gynecol Reprod Biol 2012
  - Diaz-Garcia et al Acta Obstet Gynecol 2012
  - Akin et al Hum Reprod 2013
  - Diaz- Garcia et al Acta Obste Gynecol 2013
  - Diaz- Garcia et al Fertil Steril 2014
- Pig from 2004
  - Wranning et al J Obstet Gynecol Res 2006
  - Avison et al Transplantation 2009
- Sheep from 2005
  - Wranning et al Fertil Steril 2008
  - Dahm Kähler et al J Obstet Gynecol Res 2008
  - Wranning et al Human Reprod 2010
-
- Baboon from 2008
  - Enskog et al Hum Reprod 2010
  - Johannesson et al Hum Reprod 2012
  - Johannesson et al Hum Reprod 2012
  - Tryphonious et al Am J Transpl 2014

"15 years"

IVF - 1963-1978

UTx - 1999-2014

Mouse

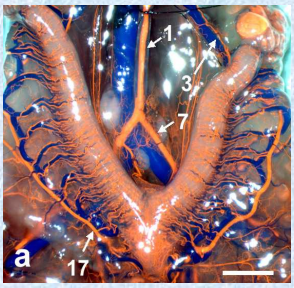

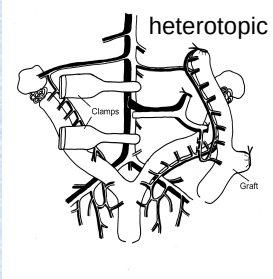

end-to-side

aorta - aorta

v. cava - v. cava

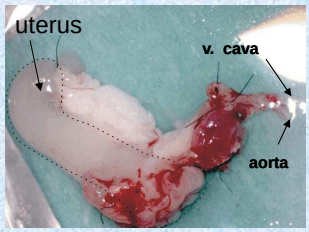

backtable preparation

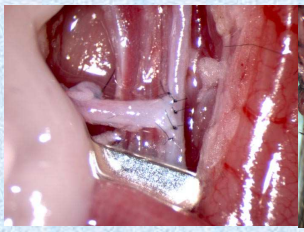

anastomosis

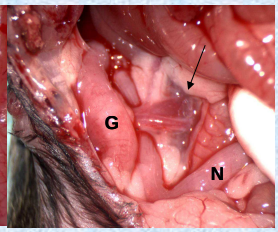

2 weeks after transplantation

Pregnancy and offspring development

Mouse

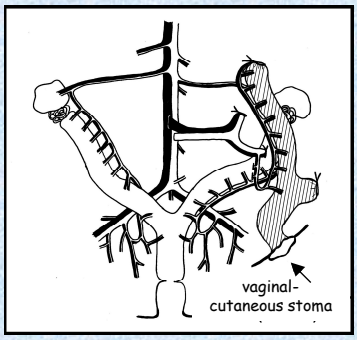

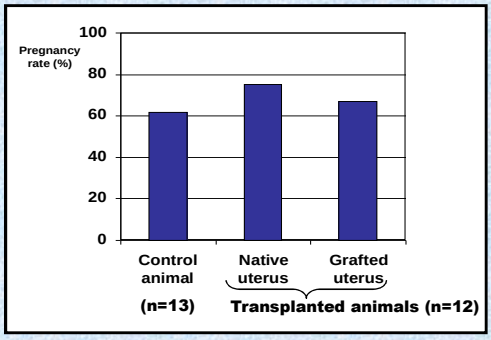

Mouse (syngenic) –ischemia and reperfusion injury (long term effects)

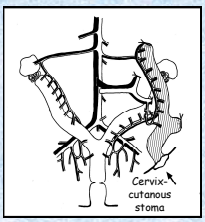

- procurement
- cold ischemia (UW) 24, 48, 72 h
- transplantation (warm ischemia, reperfusion)
- histology or ET 2 weeks post transplantation

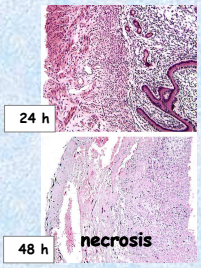

ET (n=6)

pregnant n=5 | non pregnant n=1

Sheep (autotransplantation) – ischemia (4 h) and reperfusion injury (long-term effects)

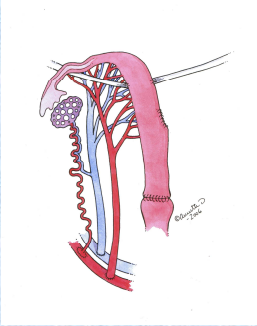

- cold ischemia 1 h
- warm ischemia 3 h (uterus + ovary transplantation)
- evaluation 2 months post op.

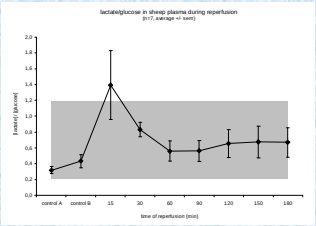

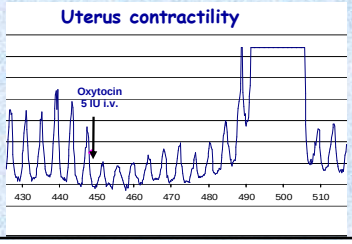

Non-human primate model - why?

- Safety issue –closest to human
  - reproductive/vascular anatomy
  - reproductive physiology
  - immunology

- Mannheimer Foundation, Miami

Adult, female, olive baboons (*Papio Anubis*; 10-14 kg) with regular menstrual cycles

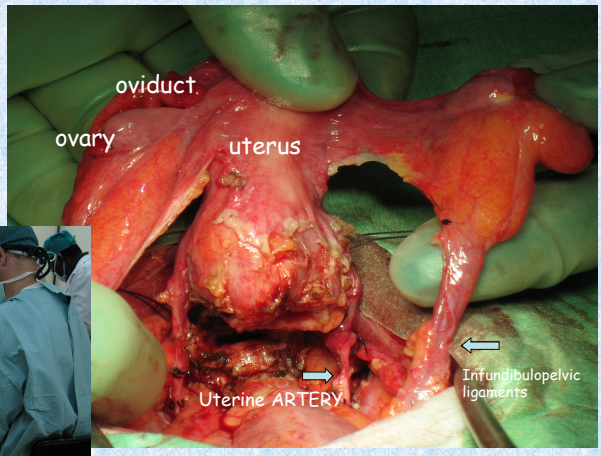

Immunosuppression

- effects on fetus (>15000 births; 2006)
  - NTPR-US, European Dialysis and Transplant Association Registry, UK Transplant Pregnancy Registry
  - no increased risk of congenital malformation (McKay, Josephson NEJM 2008)
  - **prematurity, SGA, preeclampsia ???**
    - Källen et al BJOG 2005, Pregnancy outcome after maternal organ transplantation in Swede.
    - *All births in Sweden between 1973-2002*
    - *Before transplantation: 980, After transplantation: 152*
    - "Similar risks in pregnancies before and after organ transplantation" (980 before - 152 **after)**
    - **No increase in malformation reported**

Rat - orthotopic placement

Recipient hysterectomy

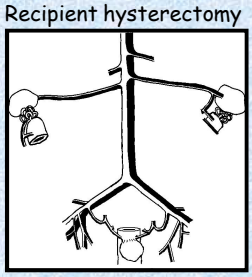

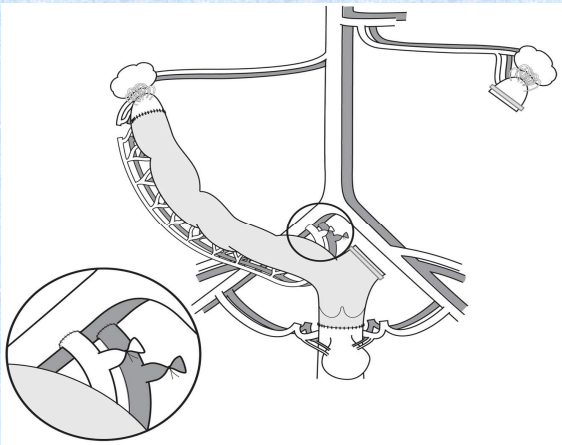

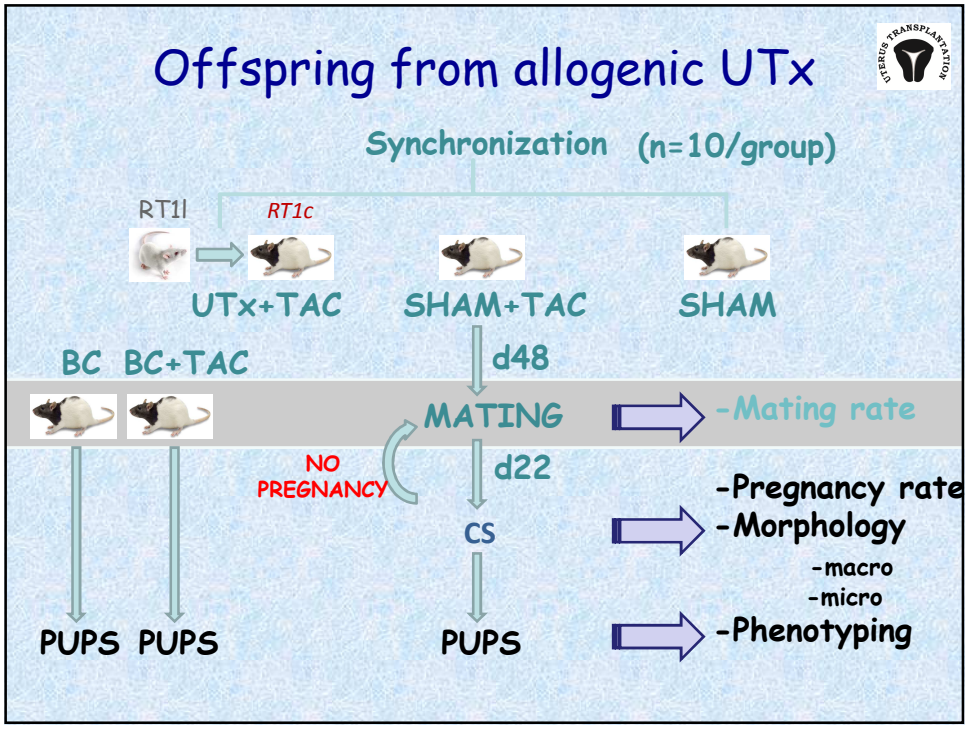

PHENOTYPING - normal

- ✓ Birth weight
- ✓ Metabolism
  - •Weight gain (weekly)
  - •Body composition (DEXA)
  - •Glucose overload
  - •Basal metabolism (Somedic)
- ✓ Cardiovascular
  - •BP
  - •Functional echocardio
- ✓ Behavior
  - •Anxiety
  - •Memory
- ✓ Urinary
  - •Kidney function
- ✓ Fertility
- ✓ Aging

Preclinical report on allogeneic uterus transplantation in non-human primates

Johannesson L, **Enskog** A, Mölne J, Diaz-Garcia C, Hanafy A, Dahm-Kähler P, Tekin A, Tryphonopoulos P, Morales P, Rivas K, Ruiz P, Tzakis A, Olausson M, Brännström M.
Hum Reprod. 2013 Jan;28(1):189-98.

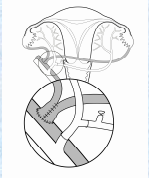

- live donor concept used (100% survival)
- durations:retrieval 3h, transplantation 3.5 h
- single immunosuppress. (IS) with tac – reject. in 3 months
- triple IS (tacrolimus, MMF, corticosteorids) needed for 3 months survival
- cervical biopsies ok for rejection diagnosis

Allogeneic uterus transplantation in baboons: surgical technique and challenges to long-term graft survival

Tryphonopoulos P, Tzakis AG, Tekin A, Johannesson L, Rivas K, Morales PR, Wagner J, Mölne J, Enskog A, Diaz-Garcia C, Dahm-Kähler P, Berho M, Zimberg S, Falcone T, Ruiz P, Olausson M, Brännström M.
Transplantation. 2014 Sep 15;98(5):e51-6.

- deceased donor concept (donor 0.5 h, recipient 2.5h)
- IS with ATG followed by tac and corticosteroids
- rejection episodes treated with ATG
- survival for up to 14 months with reversed (ATG) rejection episodes
- grading system for rejection (cervical and endometrial biopsies)
  - borderline
  - mild
  - moderate
  - severe

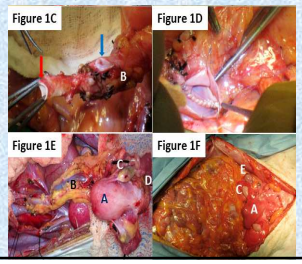

Gothenburg – live donor UTx

Based on > 10 years of animal UTx-research

May 2012 – ethics approval
- case series (n=9)
- paid 100% by private research foundation
- surgery on wekends

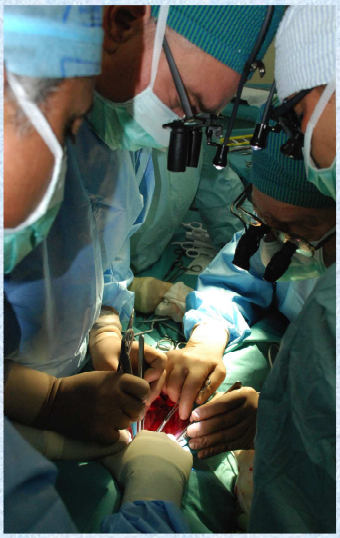

Recipients

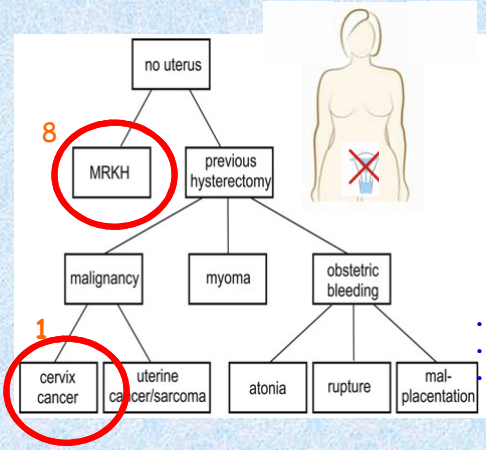

- age 27-38 years
- healthy
- non-smokers
- BMI 21-25

MRKH (n=8)- kidney
- 3 single normal kidney
- 1 single pelvic kidney

- Cervical cancer (squamous) stage Ib1
- Radical hysterectomy (ovaries preserved) 2005
- No adjuvant therapy

- IVF before
  - ascertain fertility within couple
  - cryopreserve embryos for single ET 12-18 months after UTx

Donors

- BMI < 28
- no systemic diseases
- normal pregnancy (one Cs Ok)
- no malignancy
- relatives and friends
  - mother (n=5)
  - mother´s sister (n=1)
  - sister (n=1)
  - mother-in-law (n=1)
  - family friend (n=1)

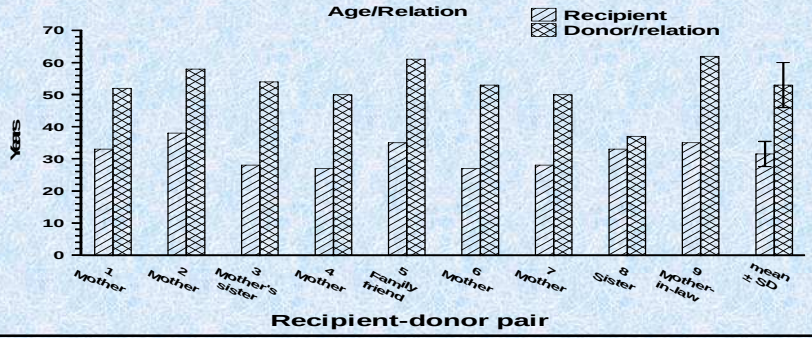

Donor surgery

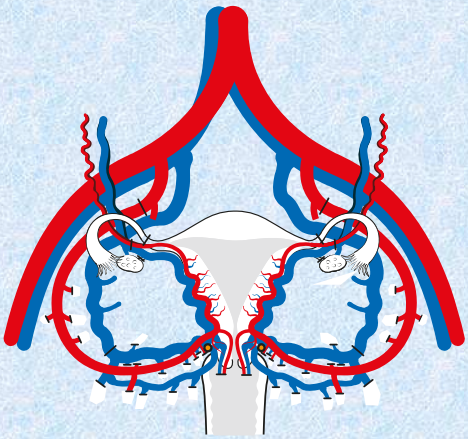

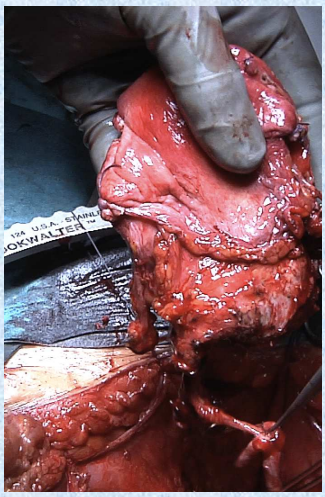

- DISSECTION OF UTERINE VEIN(S) TO INSERT INTO INTERNAL ILAC VEIN

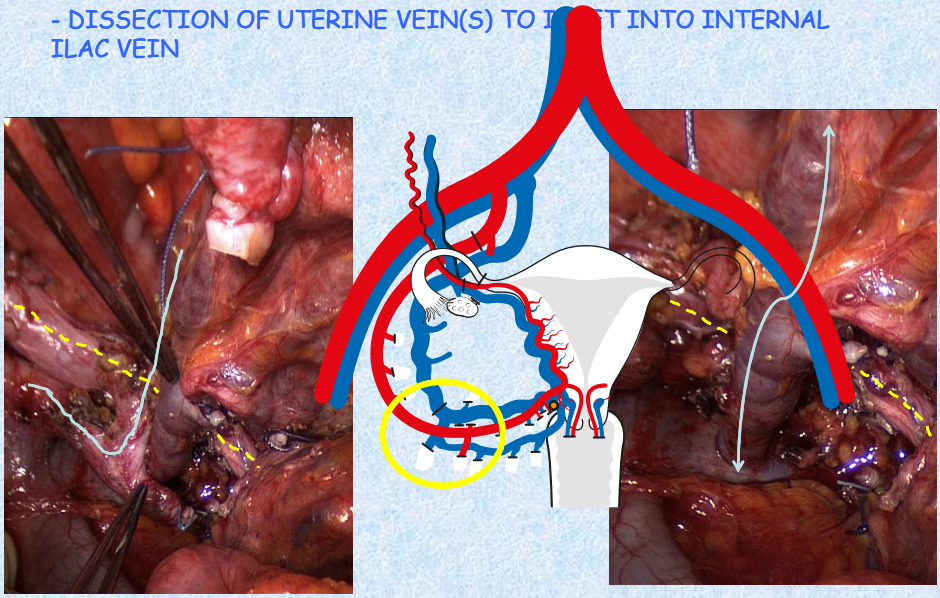

- CLAMPING OF INTERNAL ILIAC ARTERY (DISTAL TO GLUTEAL ARTERY ★)
- CLAMPING TO OBTAIN PATCH OF INTERNAL ILAC VEINç

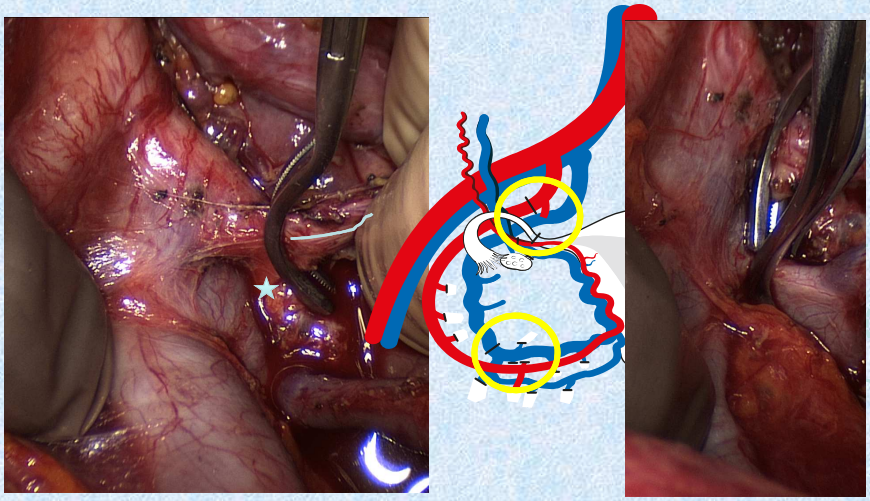

- SEVERANCE OF INTERNAL ILIAC ARTERY
- INTERNAL ILIAC VEIN PATCH(SEGMENT

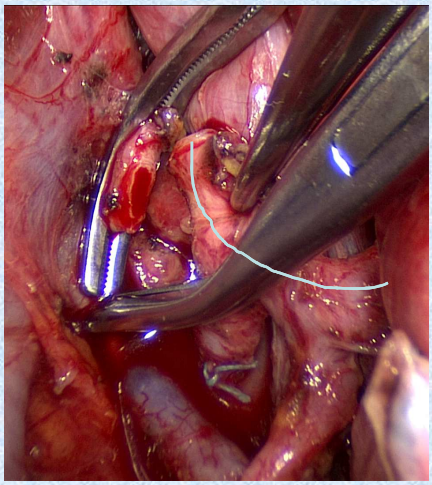

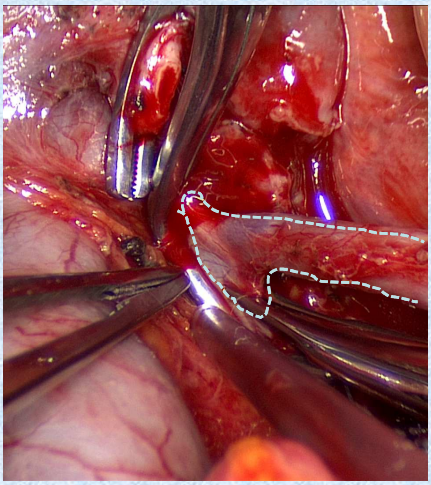

Durations - anesthesia and surgery

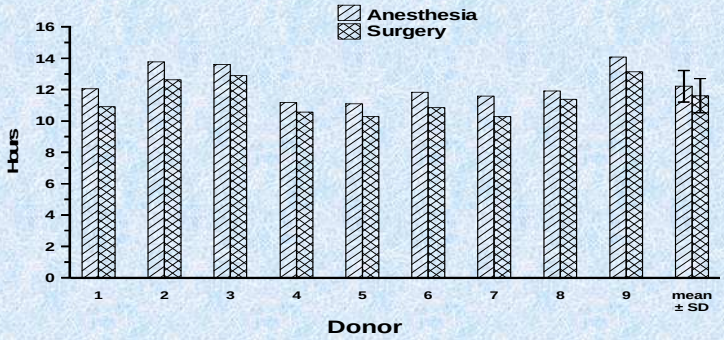

Donor surgery

- duration 10-12h
  - (radical hysterectomy 2.5 h)
- time consumption
  - ureteric dissection
  - isolation of uterine veins

- no ICU
- 6 days hospital stay

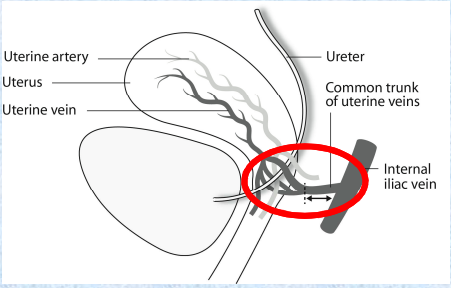

One grade 3 (Clavien-Dindo system) complication (donor 2):
- ureteric-vaginal fistula 2 weeks after surgery;
- ureteric implantation 3 months later, then in good health

Recipient surgery

- SEPARATION OF BLADDER AND RECTUM FROM UTERINE RUDIMENT

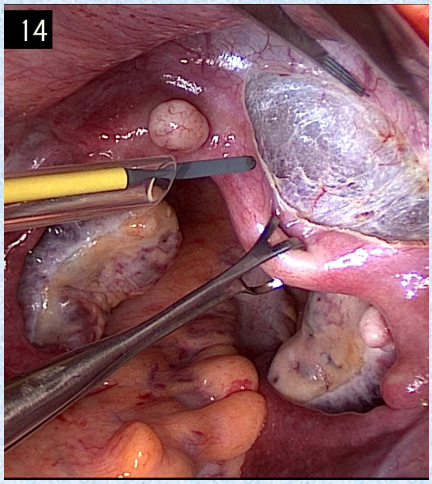

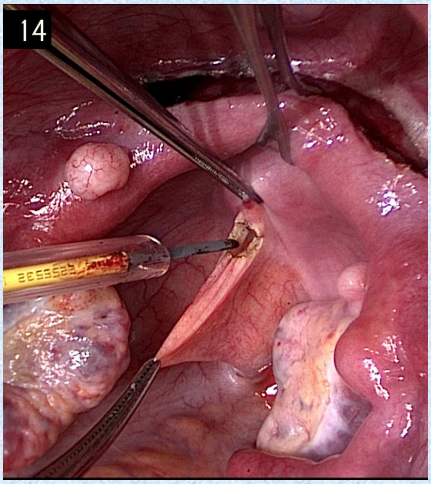

-CLEAVAGE OF UTERINE RUDIMENT TISSUE
- FIXATION SUTURES (2-0 PROLENE) IN SACROUTERINE LIGAMENTS

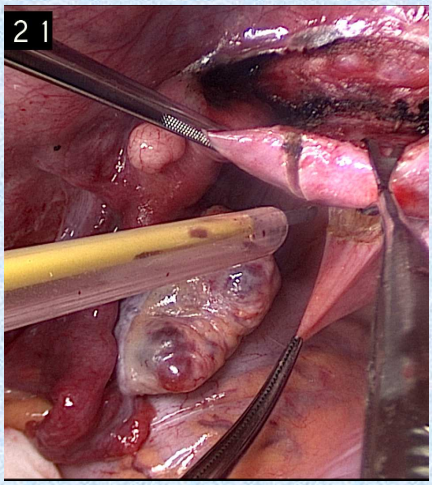

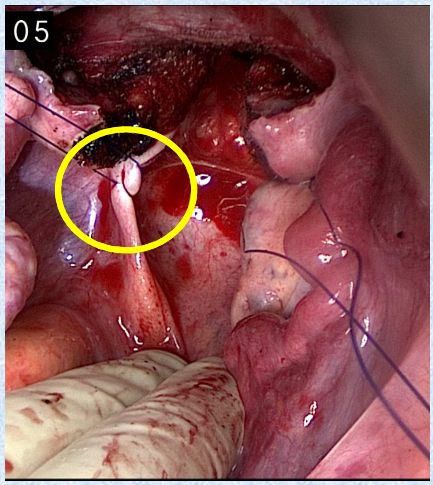

-FIXATION SUTURES IN CLEAVED UTERINE RUDIMENT AND ROUND LIGAMENTS

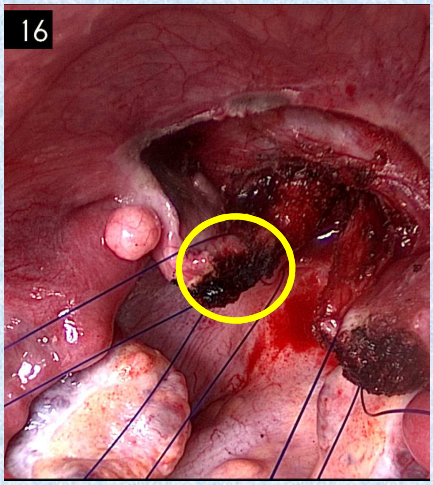

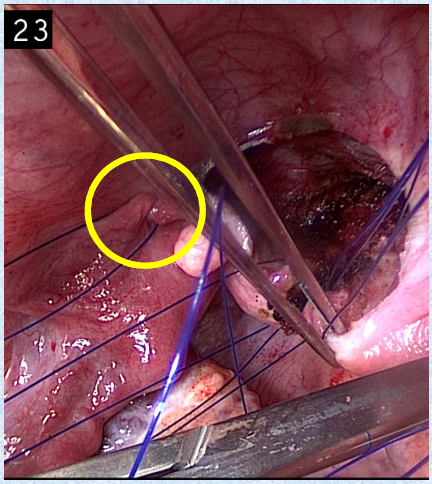

VENOUS END-TO-SIDE ANASTOMOSIS (8-0 PROLENE)

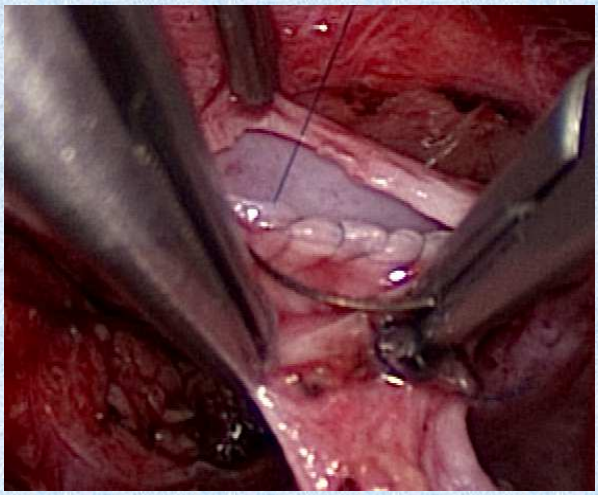

END-TO-SIDE ANASTOMOSIS (7-0 PROLENE)

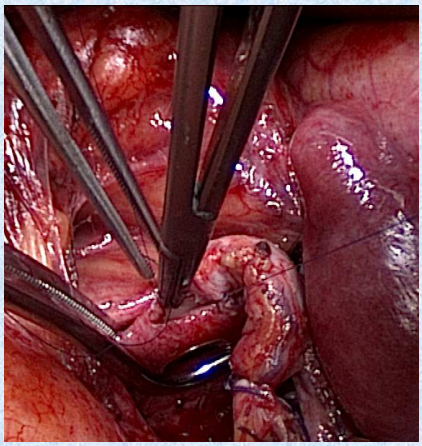

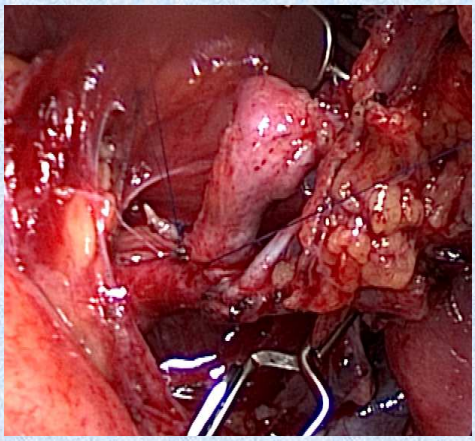

Vaginal anastomosis

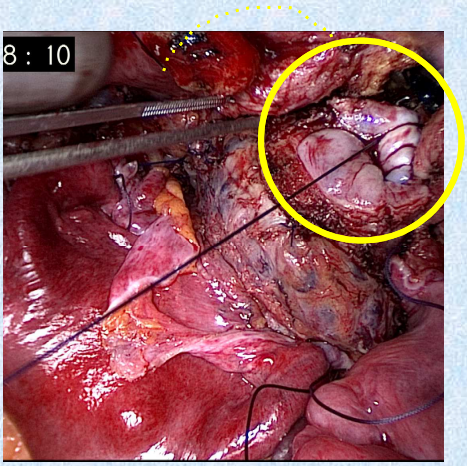

Fixations

- sacrouterine ligaments
- uterine rudiments to lateral cervix
- round ligaments
- extensive bladder peritoneum overlay

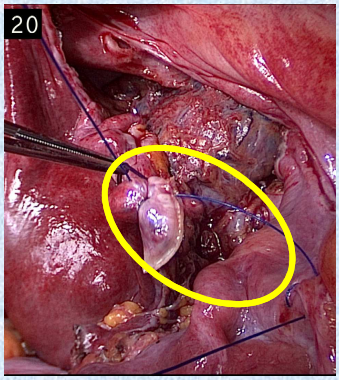

- OVERLAYING BLADDER PERITONEUM OVER BLADDER

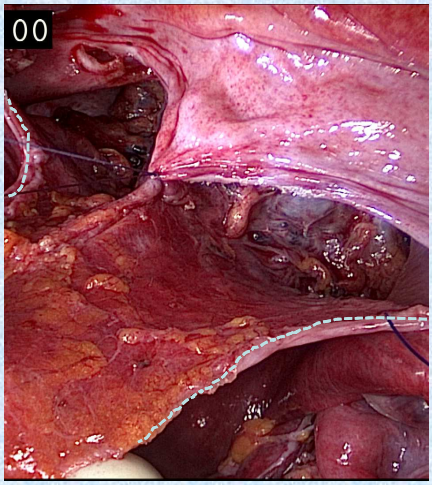

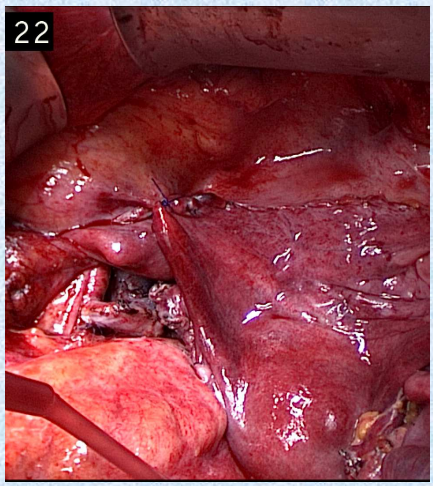

Recipient surgery

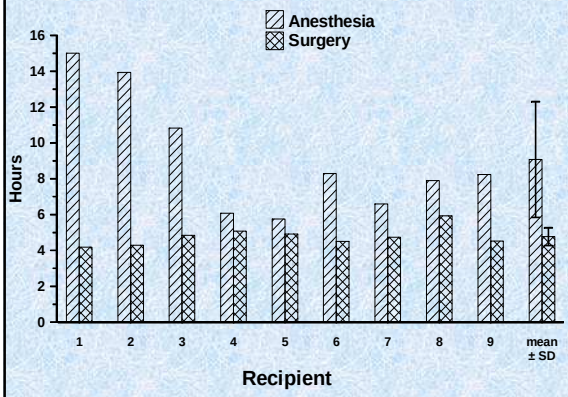

- No blood transfusion
- No ICU
- hospital stay 3-9 days

- regular menses from 1-2 months in 7 patients

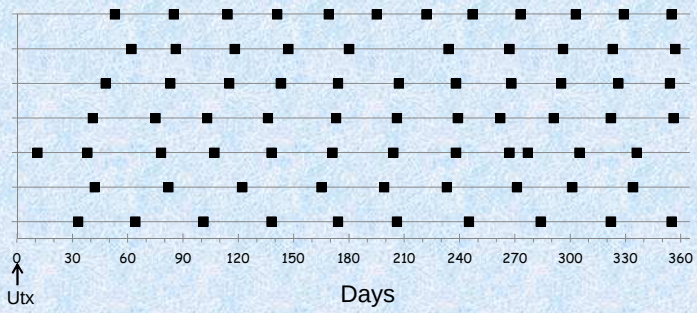

- single embryo transfers (sET) in 7 patients
- delivery by c-section
- hysterectomy after maximum two births

Immunosuppression

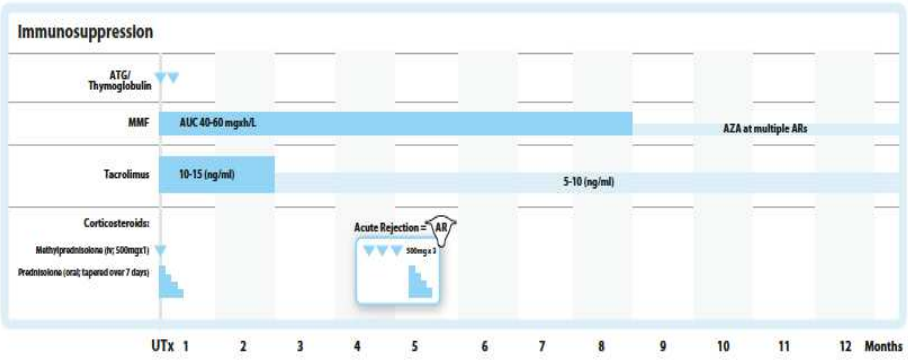

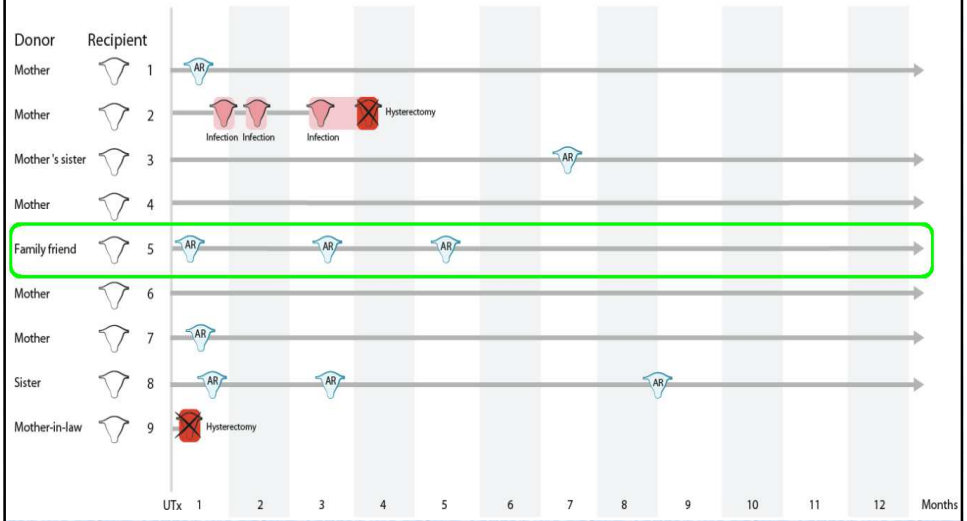

The first clinical uterus transplantation trial; a six-month report. Brännström et al Fertil Steril 2014; 101:1228-36

Uterus transplantation trial: one-year outcome. Johannesson et al Fertil Steril 2015; 103:199-204

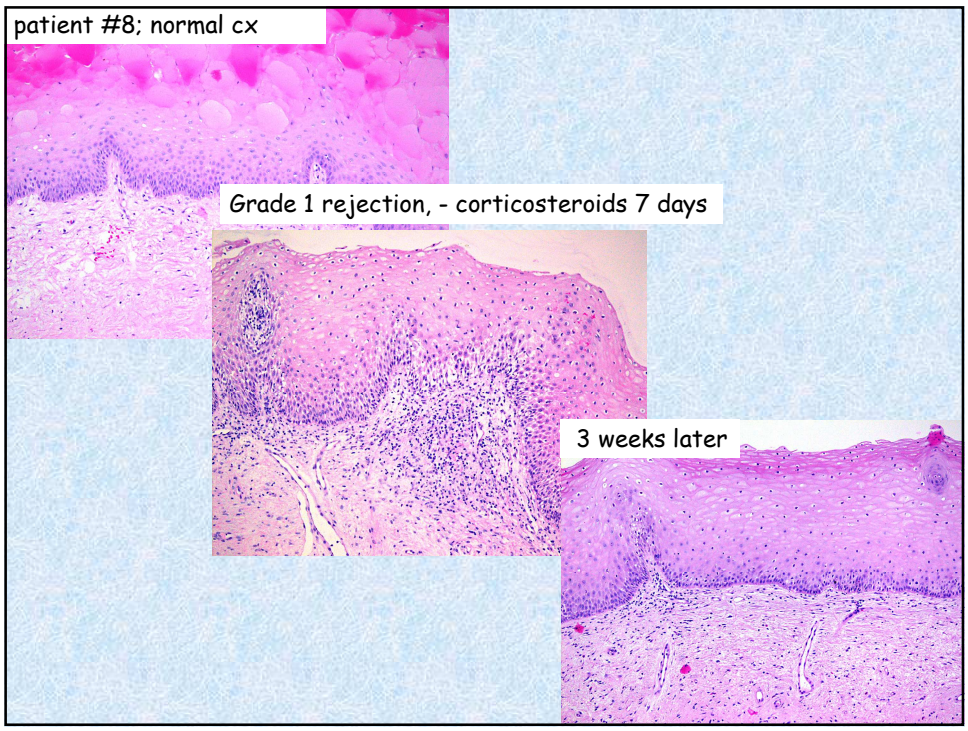

Livebirth no. 1

- Recipient
  - 35 years
  - MRKH (single kidney)
  - BMI 21
- Donor
  - 61 years, non-related friend
  - 2-parous (vaginal, term deliveries)
  - BMI 20
- Surgery
  - Donor 10 h 7 min (blood loss 0.6L)
  - Recipient 4 h 55 min (blood loss 0.75L)
  - Total (cold+warm) ischemia 2h 19min
- 12 months
  - 3 reversible mild rejection episodes

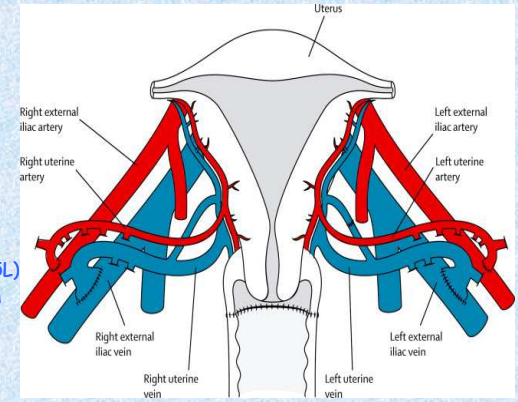

- pregnant after her first single embryo transfer
- triple immunosuppression (tac, azath, predn.) because of frequent rejection episodes

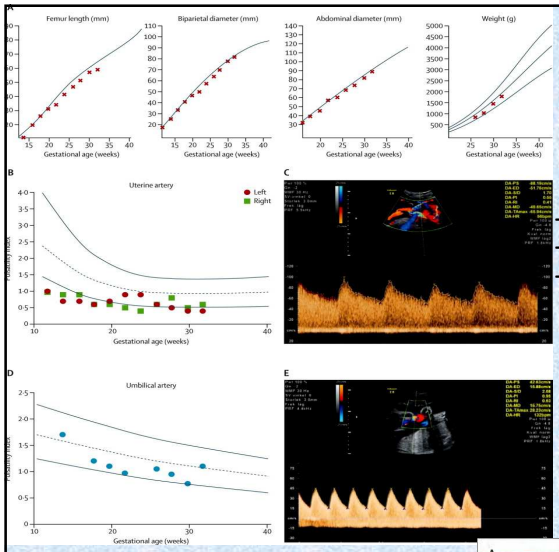

- normal fetal growth curves
- uterine artery PI – normal to low
- umbilical artery PI - normal

- mild rejection w. 18

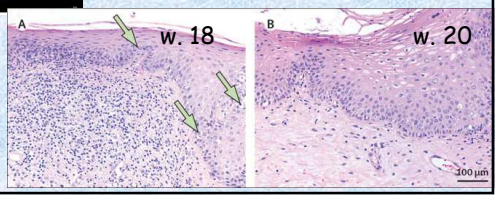

"Vincent"

PE in 31+5

BP 180/120
headache
proteinuria
lowered platelets

C-section 31+6 (1775 g (-11%) Apgar 9, 9, 10)

Today: 13,5 months – 12kg

Possible PE causes
- Immunosuppression
- Aged uterus (63 at chilfbirth)
- IVF
- **Single kidney**

Livebirth no. 2 – "Albin"

- Mother-to daughter
  - Donor
    - Para 3
    - Age 50
    - Premenopausal
  - Recipient
    - MRKH
    - Double kidneys
    - Age 28
- Surgery
  - 11h 35min
  - 4h 4
- Pregnant at first blastocyst transfer

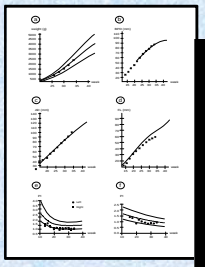

- **cesarean section (34+4) due to cholestasis**
- **Apgar score 9-10-10. birth weight 2335g (-7%)**
- **NO PREECLAMPSIA**

Livebirth no. 3 – "Henry"

- Mother-to daughter
  - Donor
    - Para 2
    - Age 53, premenopausal
  - Recipient
    - Age 32
    - cervical cancer (scc, stage 1b, radical hyst. 2005)
- Surgery
  - 10h 54 min
  - 4h1 0min
- Pregnant at 4th sET (day 2-3 embryos)
- Single immunosuppression (tac.)

- c-section in week 35+1 (nov 2014)
- healthy, 2700g (+4%)
- Today – almost 1 year, 11,5kg



Livebirth no. 4 – "Cash Douglas"

- sister to sister pregnant at 6th sET
- **single kidney**
- cholestasis week 33+5
- PROM and **PE 34+1**
- C-section (June 27, 2015)
- 3075 g (+19%)
- Today 4 mths, 7 kg



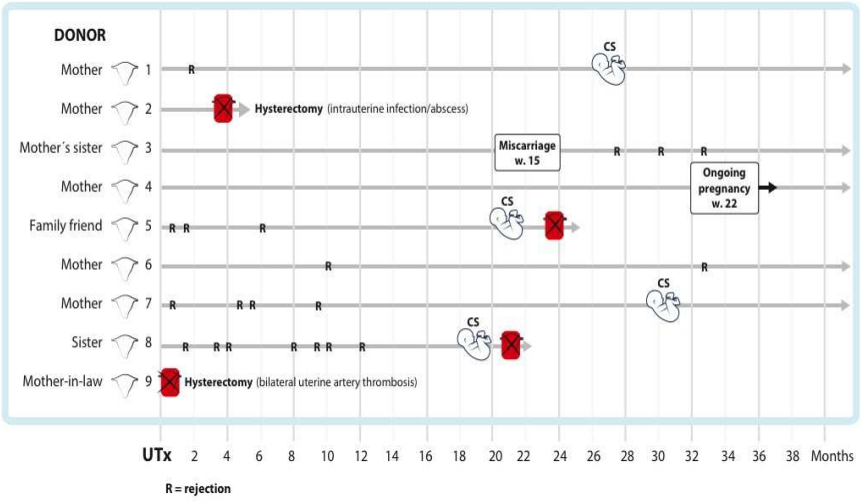

Summary

- **86 % clinical pregnancy rate**
  - 4 delivered (all boys)
  - **1 ongoing (week 24)**
  - 1 miscarriage (w. 14)
  - 1 no pregnancy yet
- **57%** (exp. ≥ 71%) **take-home-baby rate**
- **Better pregnancy results than IVF**

Conclusion

- UTx is an effective surgical method to treat uterine factor infertility
- AUFI does not longer exists
- UTx needs to be developed further

UTx -Team effort !!!!!

Gyne-oncology
- Mats Brännström
- Pernilla Dahm Kähler
- Janusz Marcickiwiecz

Transplant surgery
- Michael Olausson
- Andreas Tzakis
- Niclas Kvarnstrröm

Gynecology
- Cesar Diaz
- Ash Hanafy
- Liza Johanesson
- Randa Akouri

Transplantation nephrology and IS
- Jana Ekberg

Anesthesiology
- Anders Enskog

Reproductive medicine
- Lars Nilsoon
- Kenny Rodriguez

Obstetrics
- Hans Bokström

Psychology
- Stina Järvholm