Moderne Brustchirurgie: Von der Ästhetik bis zur Rekonstruktion



Vivantes

Brustkrebschirurgie

Brustkrebs ist kein medizinischer Notfall !

Brustentfernung *gleichwertig* Brusterhaltung + Nachbestrahlung



Umberto Veronesi



Bernard Fisher

Vivantes

Oncoplastic Breast Surgery: Past, Present, and Future Directions in the United States

Albert Losken, M.D.
Maurice Y. Nahabedian, M.D.
Atlanta, Ga.; and Washington, D.C.

Plastic & Reconstructive Surgery 2009;124(3):969-972

Treatment models differ in various parts of the world. Breast cancer surgery **and** reconstruction are often performed by gynecologists in Germany who have skillfully developed oncoplastic breast centers and offer state-of-the-art care for the diagnosis and management of breast disease

Ann Surg Oncol (2010) 17:S242–S244
DOI 10.1245/s10434-010-1240-8

Annals of
SURGICAL ONCOLOGY
OFFICIAL JOURNAL OF THE SOCIETY OF SURGICAL ONCOLOGY

ORIGINAL ARTICLE – AMERICAN SOCIETY OF BREAST SURGEONS

How I Do It: Oncoplastic Breast-Conservation Surgery

Melvin J. Silverstein, MD[1,2]

[1]Hoag Hospital Breast Program, Hoag Memorial Hospital Presbyterian, Newport Beach, CA; [2]Keck School of Medicine, University of Southern California, Los Angeles, CA

The oncoplastic surgeon must be constantly thinking, ‘‘*How can I remove this cancer with (wide) margins of normal tissue while at the same time make the patient look as good or better than she looks now*?’’

Vivantes

Moderne Brustchirurgie: Von der Ästhetik bis zur Rekonstruktion

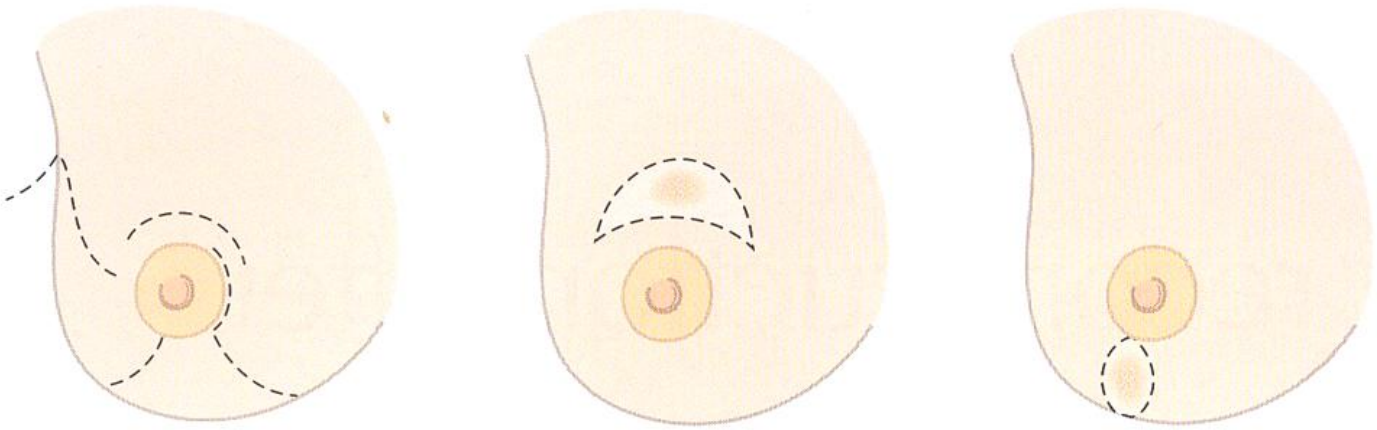

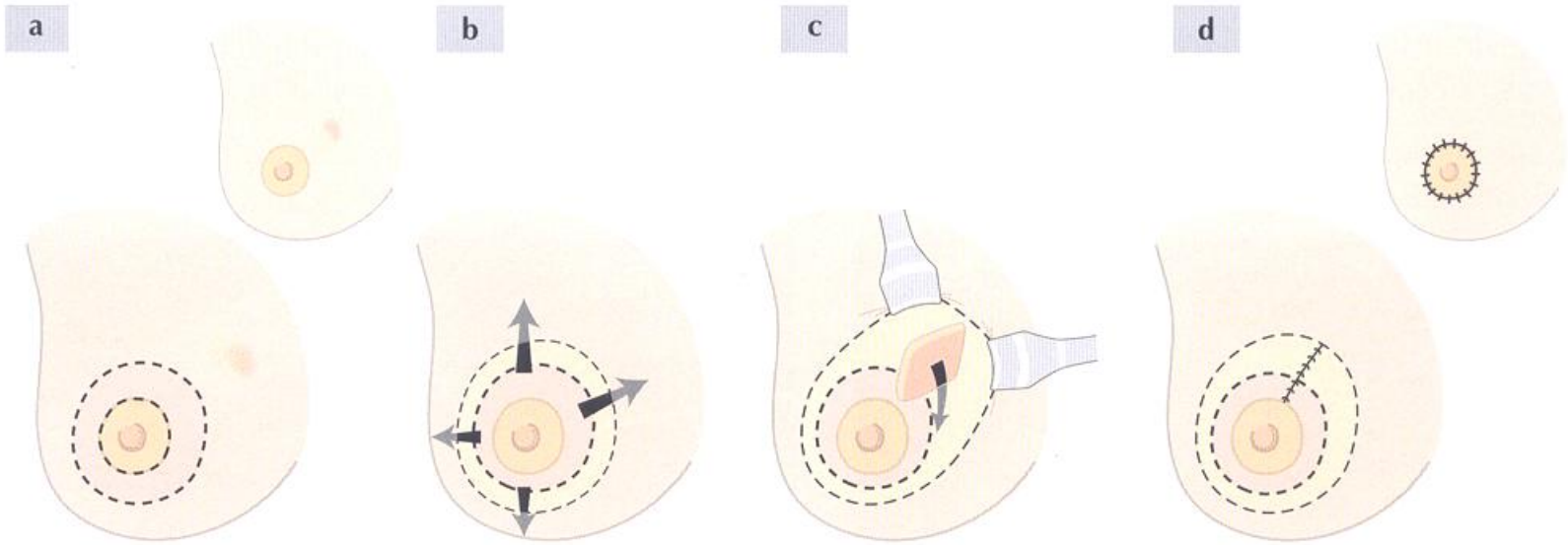

Vivantes

Brusterhaltung !

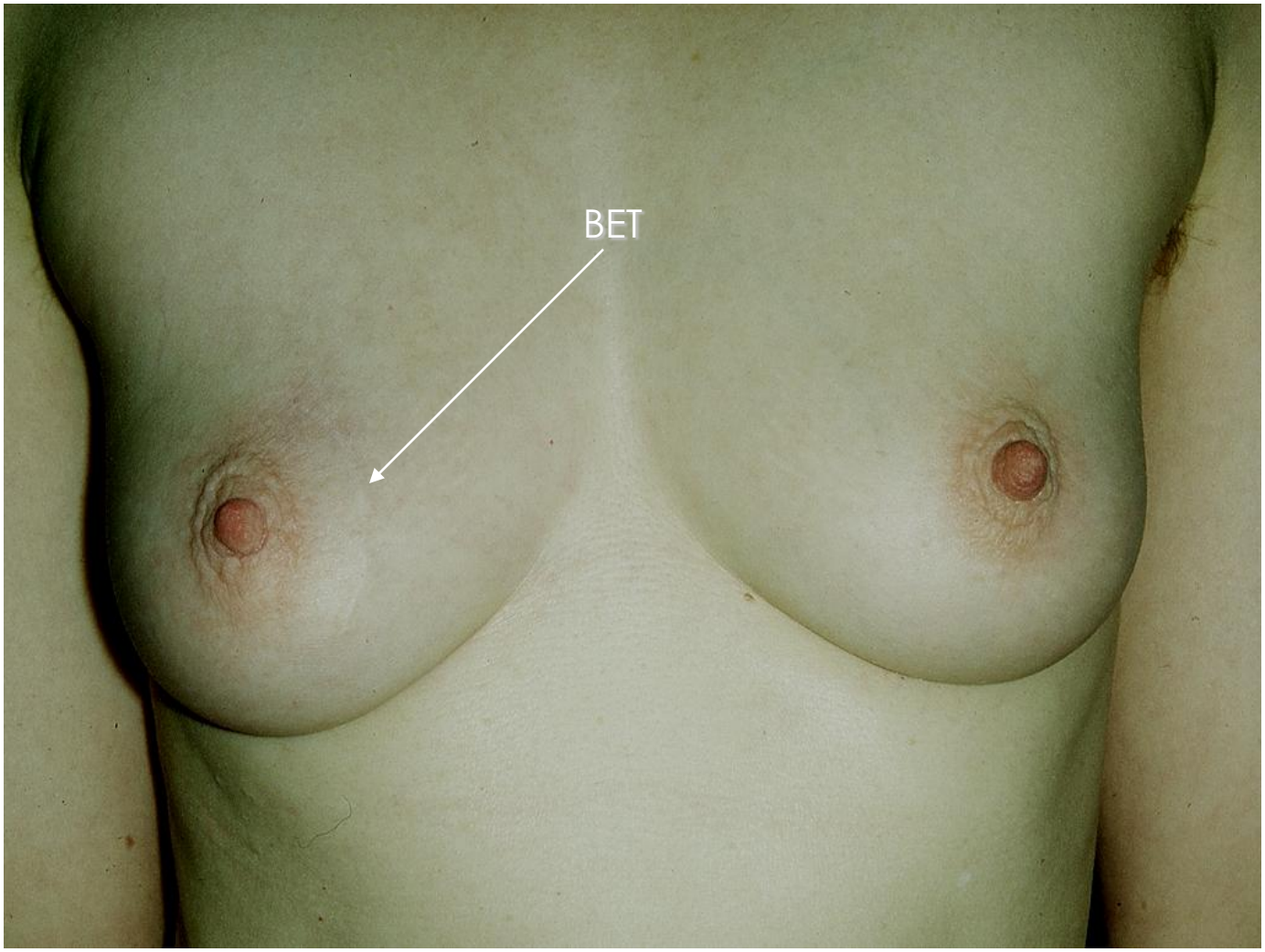

Vivantes

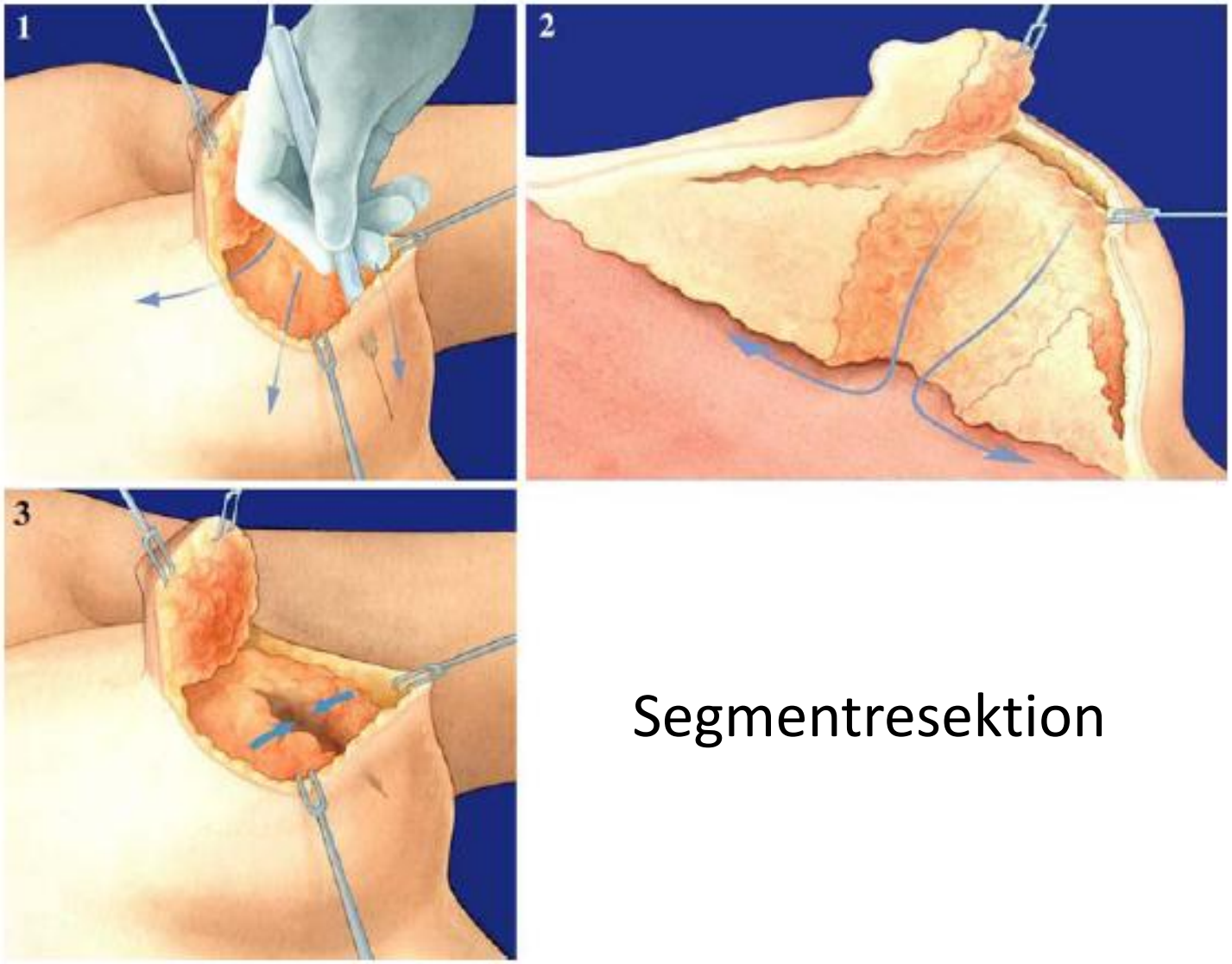

Segmentresektion

Moderne Brustchirurgie: Von der Ästhetik bis zur Rekonstruktion

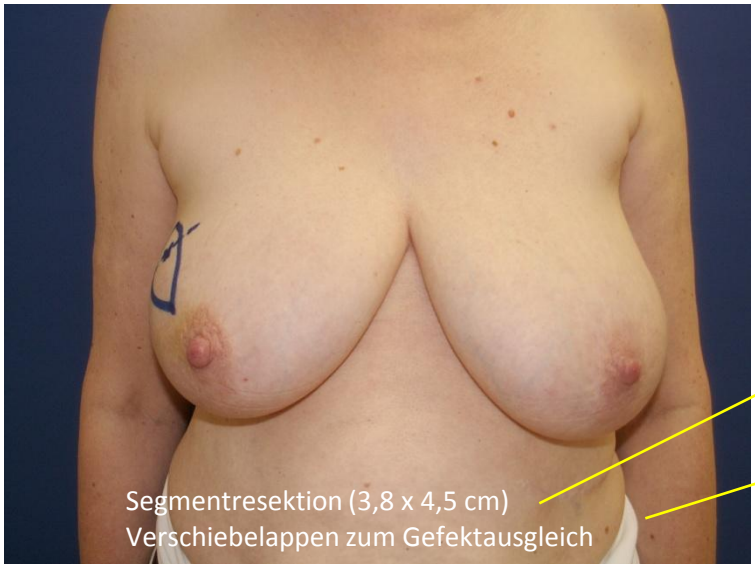



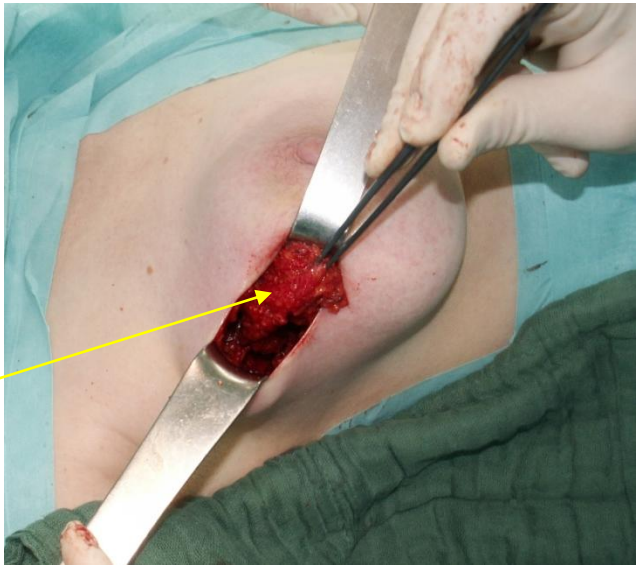

Vivantes

Moderne Brustchirurgie: Von der Ästhetik bis zur Rekonstruktion

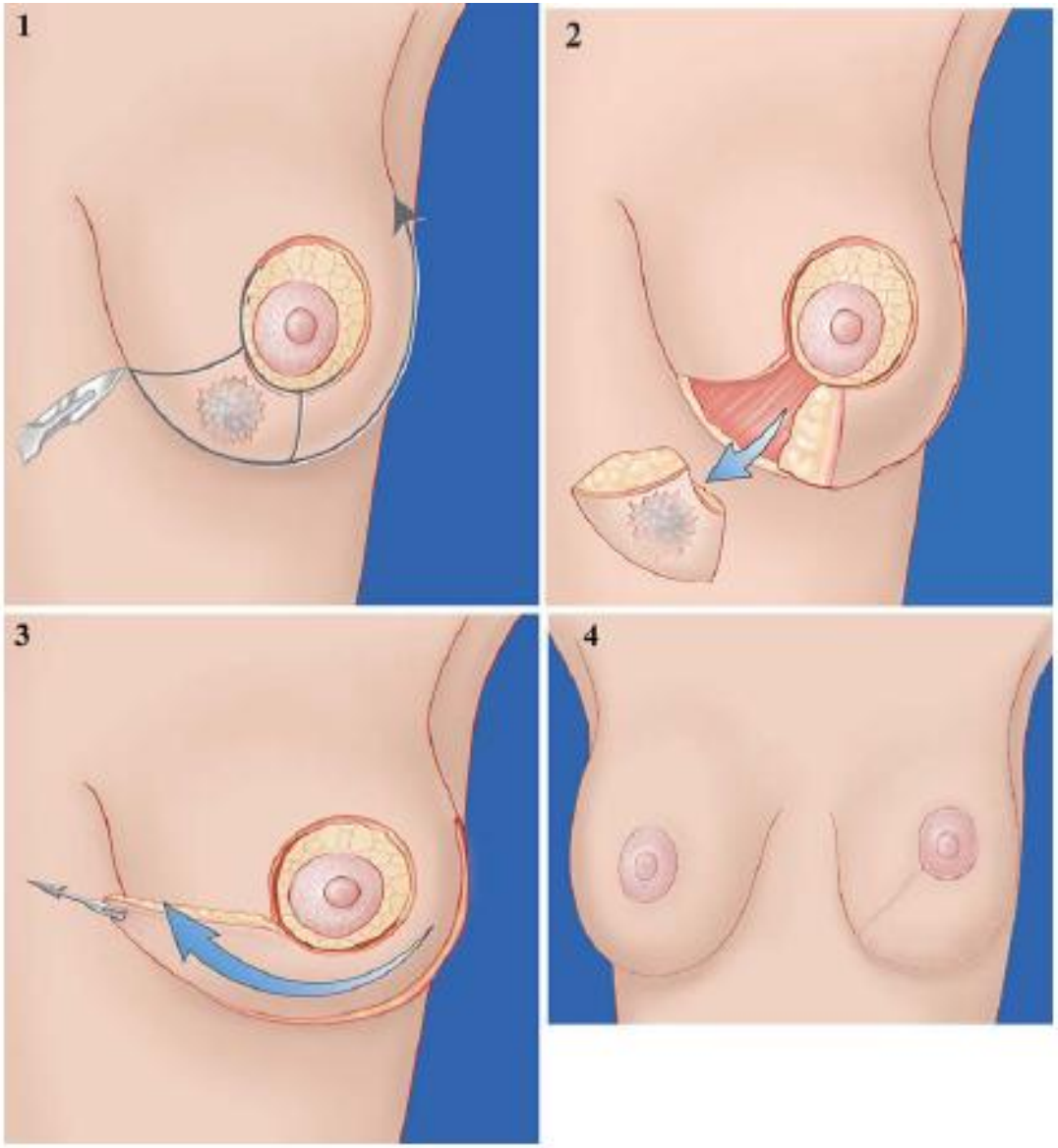

Vivantes

Moderne Brustchirurgie: Von der Ästhetik bis zur Rekonstruktion

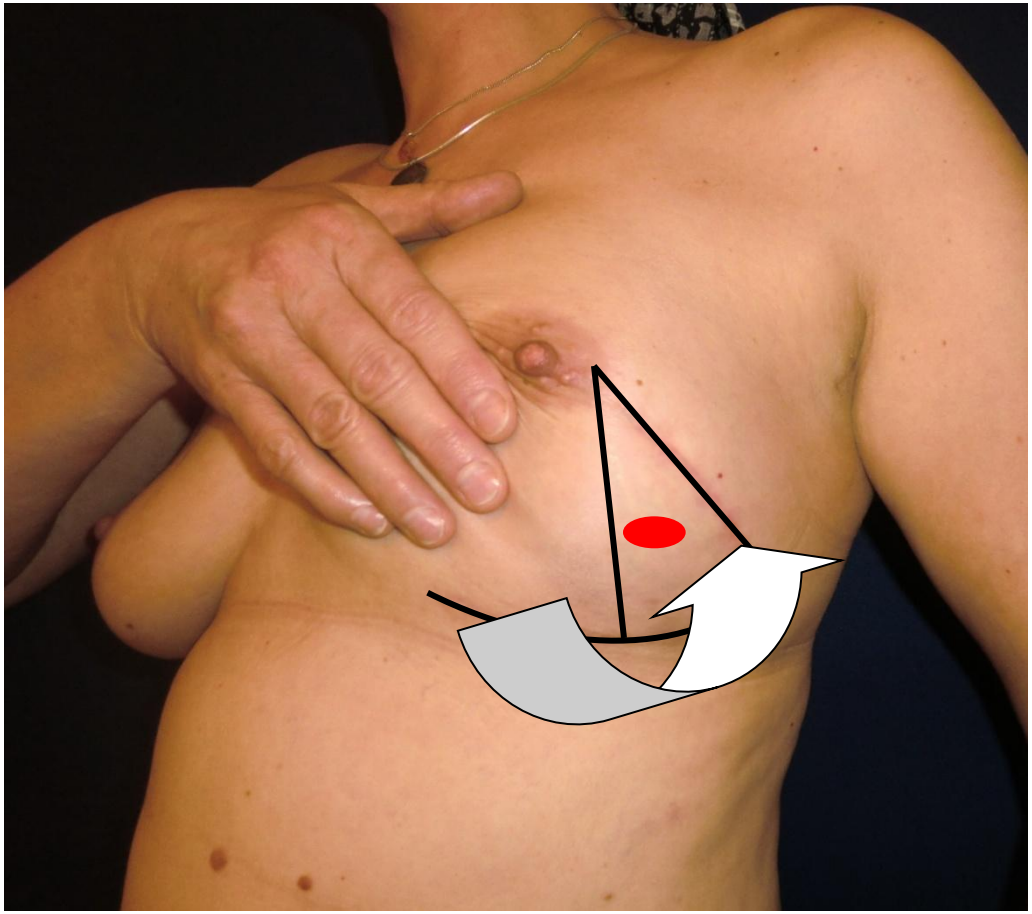

Tumorlager adaptierte Reduktionsmastopexy

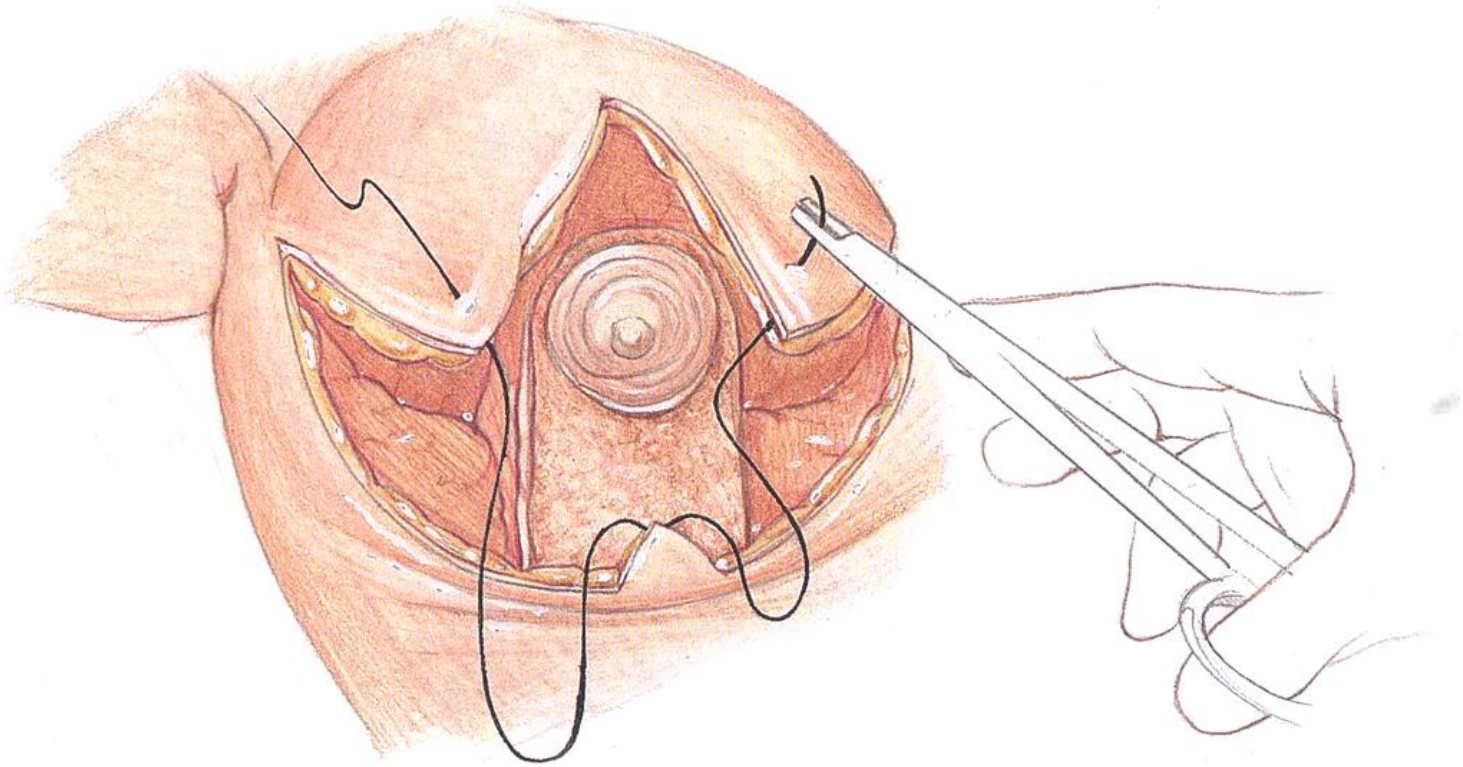

Hoffmann S: Inferior pedicle technique in breast reduction. In: Surgery of the breast. Principles and art. Spear SL, ed., 2. edition, Lippincott Williams & Wilkins, 2006.

Moderne Brustchirurgie: Von der Ästhetik bis zur Rekonstruktion

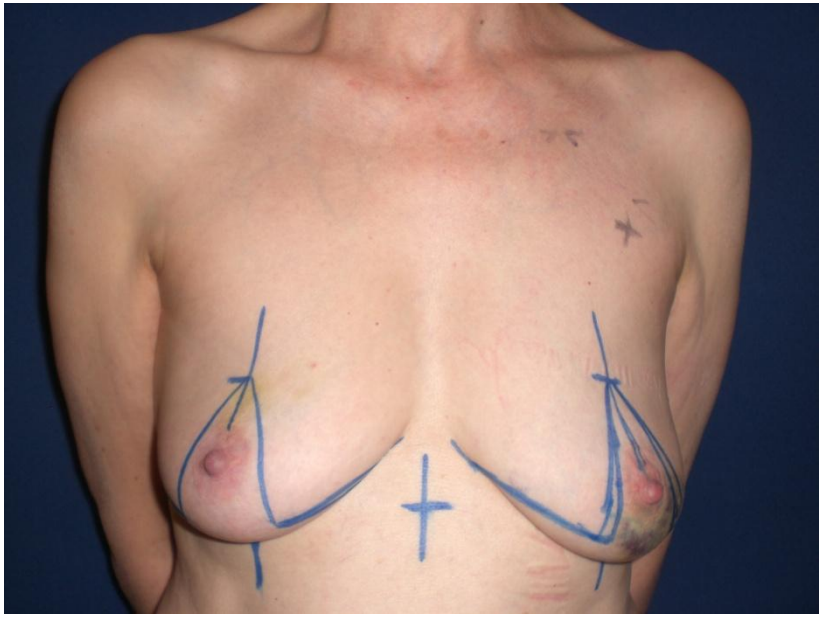

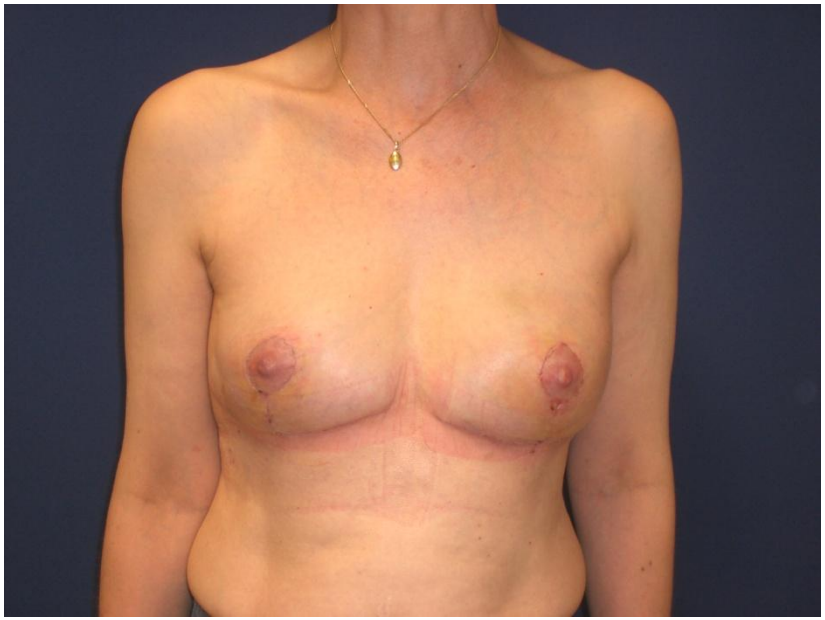

Vivantes

Implantat

one-stage (Permanentexpander)
two-stage (Expander / Implantat)

Implantat mit Netzunterstützung

Implantat und Eigengewebe

Latissimus-dorsi-flap + (Expander / Implantat)

Eigengewebe

Latissimus-dorsi-flap
TRAM-flap oder VRAM-flap (frei oder gestielt)
DIEP-flap oder SGAP-flap (frei)

Plast. Reconstr. Surg. 127: 2167, 2011

BREAST
Outcomes Article

A Head-to-Head Comparison of Quality of Life and Aesthetic Outcomes following Immediate, Staged-Immediate, and Delayed Oncoplastic Reduction Mammaplasty

Ketan M. Patel, M.D.
Catherine M. Hannan, M.D.
Margaret E. Gatti, M.P.H.
Maurice Y. Nahabedian, M.D.
Washington, D.C.

In summary, this study has demonstrated the safety and efficacy of immediate, staged-immediate, and delayed oncoplastic reduction mammaplasty. It is acknowledged that this study is mildly limited by its small sample size. The results of this study, however, highlight the improvements in aesthetic outcome as well as functional satisfaction following oncoplastic reduction mammaplasty. Larger comparative analyses focusing on improving patient satisfaction as related to aesthetic results are needed in the future as surgeons continue to strive for evidence-based improvement in outcomes.

Vivantes

Preferences in Choosing between Breast Reconstruction Options: A Survey of Female Plastic Surgeons

Hani Sbitany, M.D.
Ashley N. Amalfi, M.D.
Howard N. Langstein, M.D.

Rochester, N.Y.

Background: Female plastic surgeons are well suited to make a personal choice regarding breast reconstruction options, based on their knowledge of the actual procedures and first-hand experience with results. The authors surveyed this group to elicit their personal views on various modalities of breast reconstruction and to ascertain which types of reconstruction they would choose if faced with such a decision.

Methods: All board-certified female plastic surgeons in the United States and Canada were surveyed by means of e-mail. This survey included questions regarding basic demographic and practice data. Respondents were requested to rank desired methods of reconstruction for themselves and to cite reasons for these choices.

Results: A total of 435 surveys were sent: 350 were delivered (85 had invalid e-mail addresses), and 143 were returned (response rate, 41 percent). Overall, 66 percent

Conclusions: Board-certified female plastic surgeons exhibit a strong desire to pursue implant-based breast reconstruction over autologous reconstruction. When it was chosen, autologous reconstruction was felt to offer improved aesthetic outcomes. When making such a decision, patients can use female plastic surgeons as a resource for information, thus helping them to make an informed decision. (*Plast. Reconstr. Surg.* 124: 1781, 2009.)

comes. When making such a decision, patients can use female plastic surgeons as a resource for information, thus helping them to make an informed decision. (*Plast. Reconstr. Surg.* 124: 1781, 2009.)

Vivantes

A Retrospective Analysis of Outcomes Using Three Common Methods for Immediate Breast Reconstruction

Scott L. Spear, M.D.
Michael K. Newman, M.D.
M. Susann Bedford, M.D.
Karl A. Schwartz, M.D.
Michael Cohen, M.D.
Jaime S. Schwartz, M.D.
Washington, D.C.

Conclusion: High satisfaction rates were seen across all three reconstructive groups, with the highest satisfaction levels seen in the expander/implant group, despite higher reoperation rates and lower aesthetic scores for this group. (*Plast. Reconstr. Surg.* 122: 340, 2008.)

Options in Reconstructing the Irradiated Breast

Scott L. Spear, M.D.
James H. Boehmler, M.D.
David P. Bogue, M.D.
Amir A. Mafi, B.S.

Washington, D.C.

Plast Reconstr Surg 122: 379, 2008

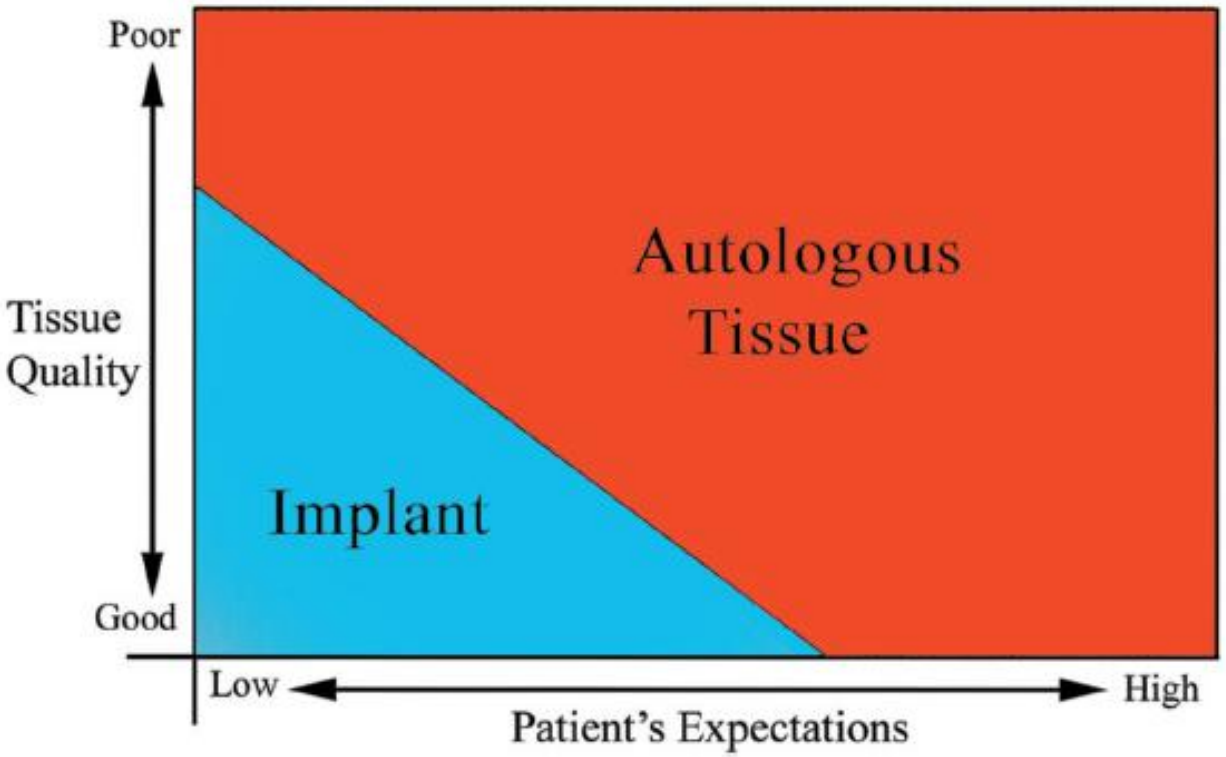

Fig. 8. Our philosophy on reconstruction with respect to tissue quality and the patient's expectations.

Vivantes

Moderne Brustchirurgie: Von der Ästhetik bis zur Rekonstruktion

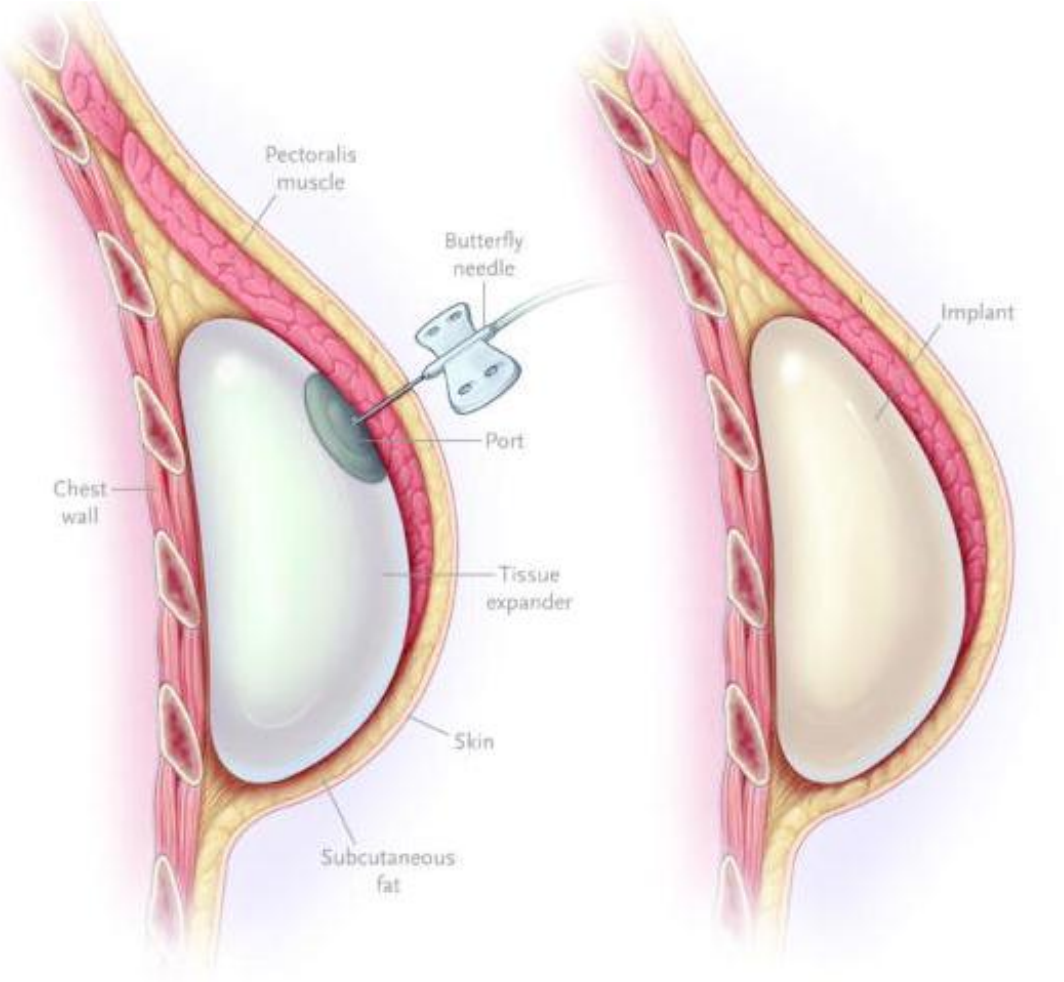

Vivantes

Placement of an implant represents the most common form of breast reconstruction in the United States, accounting for 66 075 of the total 86 424 (76,5%) breast reconstructions performed in 2009

American Society of Plastic Surgery.
2009 reconstructive surgery procedures.
www.plasticsurgery.org/media/statistics/

Immediate Placement of Implants in Breast Reconstruction: Patient Selection and Outcomes

Jason Roostaeian, M.D.
Lucio Pavone, M.D.
Andrew Da Lio, M.D.
Joan Lipa, M.D.
Jaco Festekjian, M.D.
Christopher Crisera, M.D.

Los Angeles, Calif.

Background: With the advent of skin-sparing mastectomy techniques, it became clear that immediate placement of an implant could be utilized for breast reconstruction in select patients. The authors assessed the safety, patient selection factors, and aesthetic results with this technique.

Methods: Thirty-five consecutive patients (eight unilateral and 27 bilateral) who underwent immediate implant-based breast reconstruction were analyzed. Patient data and complication rates were obtained from a retrospective chart review. Postoperative photographs were evaluated by a blinded panel and scored on a four-point scale.

Results: With a mean follow-up of 15 months, complications occurred in six patients (17.1 percent). There was one episode (2.9 percent) of skin necrosis resulting in implant loss, two episodes (5.7 percent) of postoperative infection, both of which resulted in implant salvage, and three patients who developed capsular contracture (8.5 percent). A total of 13 patients (37 percent) required additional surgery for revision. Revisions were necessary significantly more commonly in patients with a history of radiotherapy ($p = 0.047$), D-cup breast size or greater ($p = 0.018$), and ptosis of grade 2 or more ($p = 0.017$). The mean overall aesthetic score was 3.19, and upon subgroup analysis, patients with a history of radiation treatment (2.46), D-cup breast size or greater (2.64), and ptosis or grade 2 or more (2.98) had lower mean scores. Exclusion of these subgroups resulted in a mean score 3.39.

Conclusions: Immediate implant-based breast reconstruction is a safe and viable option that can provide a very good aesthetic result in appropriately selected candidates. The authors recommend caution and appropriate patient counseling in patients with a history of radiotherapy, larger breasts, and/or ptotic breasts. (*Plast. Reconstr. Surg.* 127: 1407, 2011.)

Vivantes

Breast Cancer Res Treat (2011) 127:439–446
DOI 10.1007/s10549-011-1437-y

CLINICAL TRIAL

Immediate reconstruction with implants in women with invasive breast cancer does not affect oncological safety in a matched cohort study

C. Eriksen · J. Frisell · M. Wickman ·
E. Lidbrink · K. Krawiec · K. Sandelin
Karolinska Institutet, Stockholm, Sweden

Table 4 Hazard ratio and confidence interval in total number of events

Total number of events (%)	IBR	Controls	Hazard rate ratio[a] (95% CI)	*P* value
Overall recurrence	28.4	32.8	1.2 (0.9–1.7)	0.301
Local recurrence	8.2	9.0	1.0 (0.5–1.8)	1.000
Regional recurrence	8.2	9.7	1.5 (0.8–2.8)	0.173
Distant metastases	20.3	27.1	1.4 (1.0–2.1)	0.070
Death, all causes	22.0	28.0	1.5 (1.0–2.1)	0.038
Death, breast cancer	17.0	23.0	1.6 (1.1–2.4)	0.026

[a] Controls versus immediate breast reconstruction (IBR)

IBR with implants is safe to offer patients with invasive breast cancer without any negative effect on the oncological safety.

Vivantes

Nippel-sparende Mastektomie

Abstand Mamille zum Tumor > 2 cm (Mammographie, Sonographie)

Tumor < 2 cm

Keine Multizentrizität

Kein Lymphknotenbefall

Kein subareolläres Karzinom

Dieterich M, Gerber B. 2010

Cohäsivgel-Implantat

Does the Surface Structure of Implants Have an Impact on the Formation of a Capsular Contracture?

Aesth. Plast. Surg. 31:133–139, 2007
DOI: 10.1007/s00266-006-0091-y

N. Poeppl, M.D., S. Schreml, M.D., F. Lichtenegger, M.D., A. Lenich, M.D., M. Eisenmann-Klein, M.D., and L. Prantl, M.D.

Conclusions: The histologic examination and serum hyaluronan concentration analysis showed no statistically significant difference between smooth-surfaced and textured implants (Mentor) with respect to the development of capsular contracture. On the other hand, the severity of capsular contracture showed a positive linear correlation with the degree of local inflammatory reactions, which were independent of the implant surface.

Moderne Brustchirurgie: Von der Ästhetik bis zur Rekonstruktion


Sekundäre two-stage Brustekonstruktion

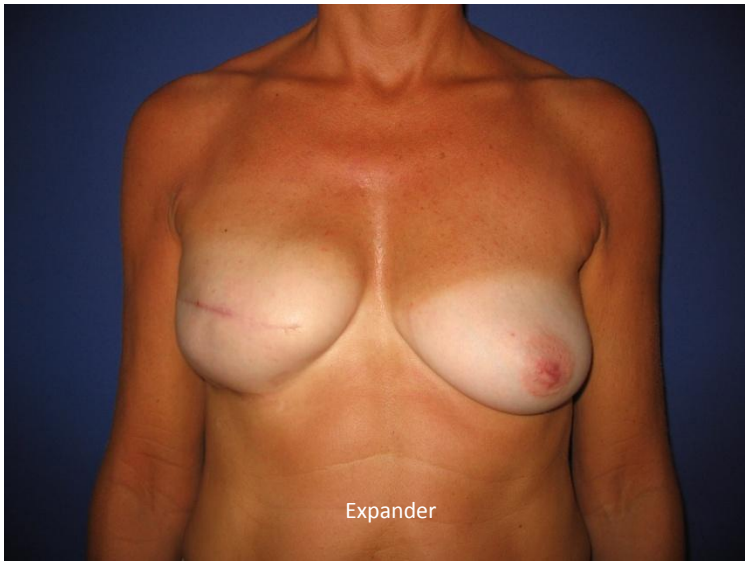
Expander

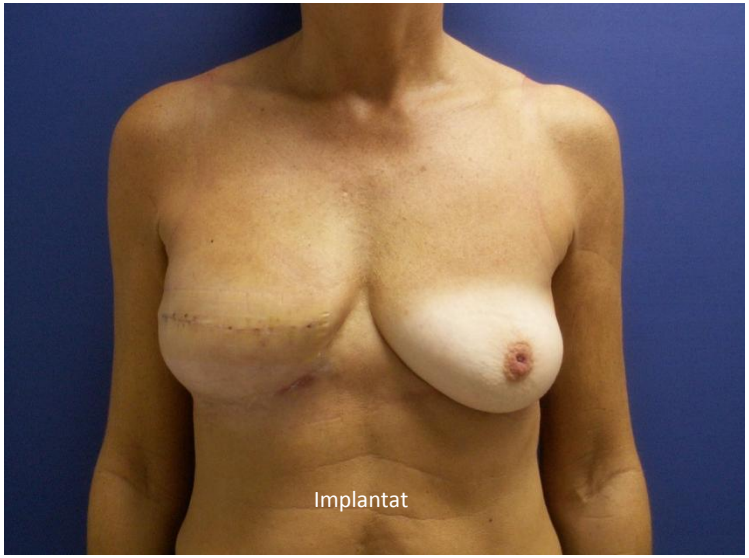
Implantat


2 Jahre postop.

Vivantes

Moderne Brustchirurgie: Von der Ästhetik bis zur Rekonstruktion

Purse-String Mastectomy with Immediate Prosthetic Reconstruction: An Improved Skin-Sparing Technique for Small Breasts

Bryant A. Toth, M.D., and Stephen P. Daane, M.D.
San Francisco, Calif.

Plast Reconstr Surg 2003;111:2333-7

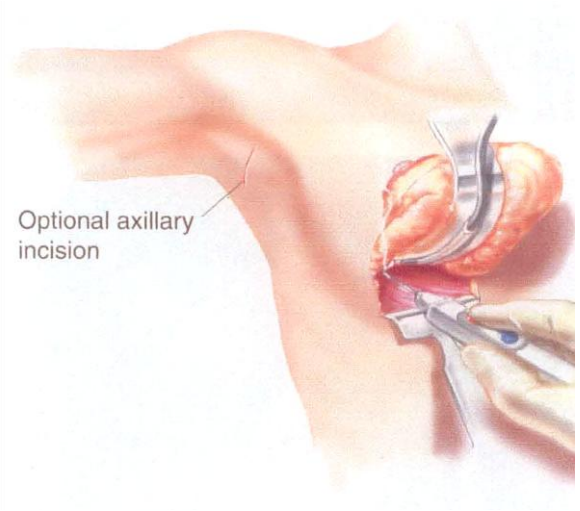

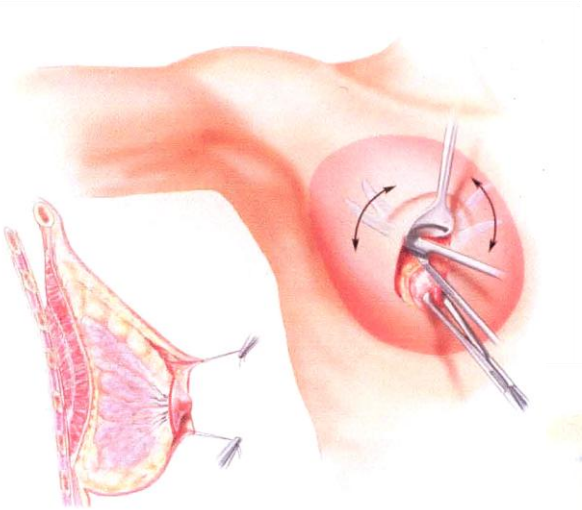

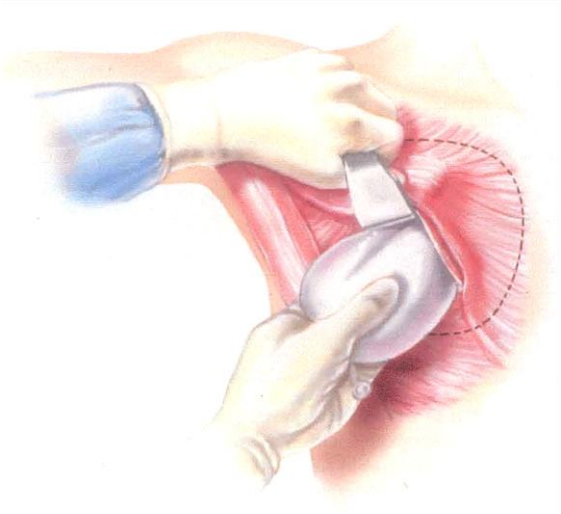

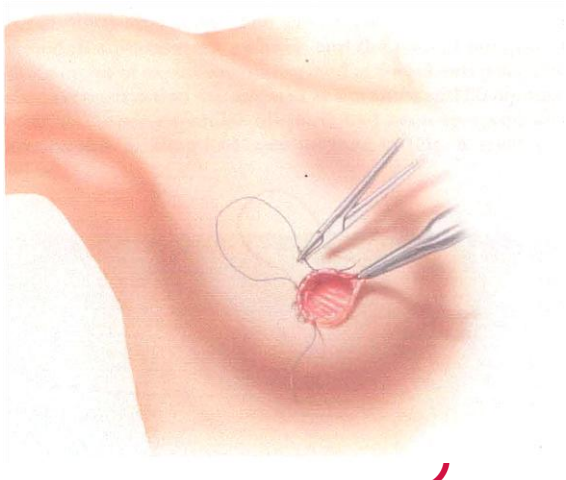

Vivantes

Moderne Brustchirurgie: Von der Ästhetik bis zur Rekonstruktion

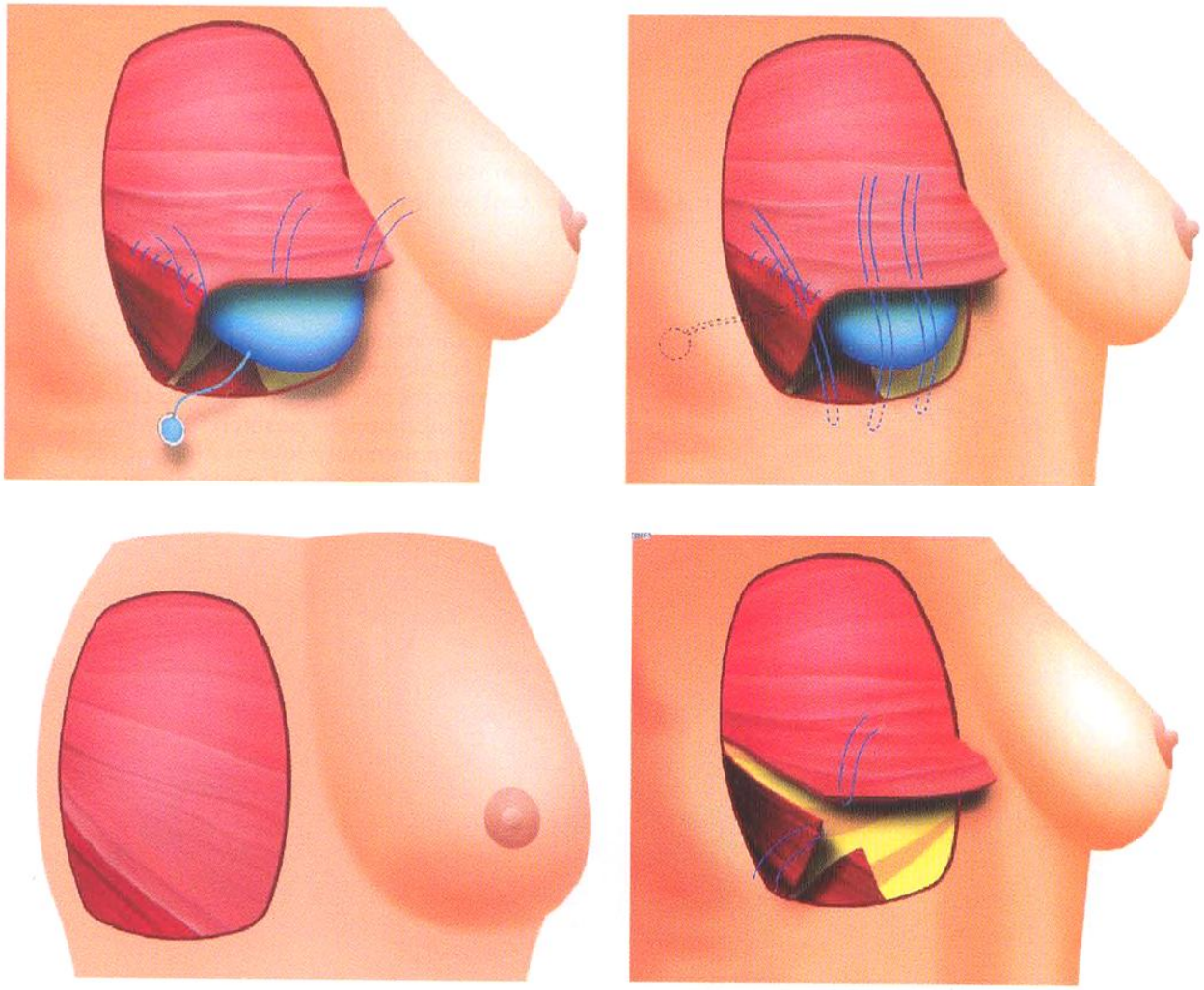

Vivantes

Moderne Brustchirurgie: Von der Ästhetik bis zur Rekonstruktion

Purse-string Mastektomie

Vivantes

Titanisiertes Polypropylennetz (TiLoop Bra©)

10/2007 Markteinführung für die Brustrekonstruktion

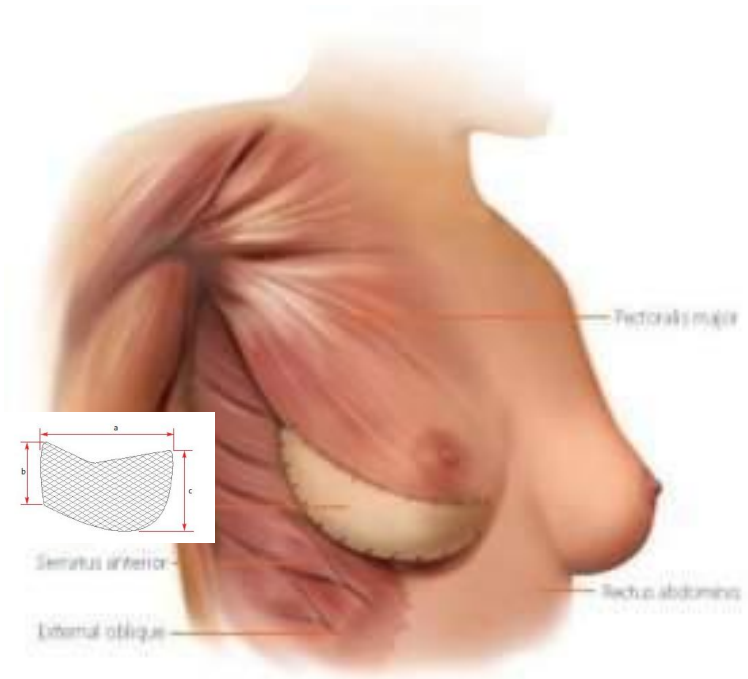

Stand 9/2011: Deutschland ca. 1400, Österreich ca. 80 Netze

Vivantes

Moderne Brustchirurgie: Von der Ästhetik bis zur Rekonstruktion

NCBI Resources How To

PubMed.gov
U.S. National Library of Medicine
National Institutes of Health

Search: PubMed | RSS | Save search | Limits | Advanced search | Help

t loop | Search | Clear

Display Settings: Summary, 20 per page, Sorted by Recently Added

Your search for *tiloop* retrieved no results. However, a search for ***t loop*** retrieved the following items.

NCBI Resources How To

PubMed.gov
U.S. National Library of Medicine
National Institutes of Health

Search: PubMed | RSS | Save search | Limits | Advanced search | Help

alloderm breast surgery | Search | Clear

Display Settings: Summary, 20 per page, Sorted by Recently Added

Results: 1 to 20 of 39

<< First < Prev Page 1 Next >

1. Techniques to reduce seroma and infection in acellular dermis-assisted prosthetic breast reconstruction.
   Sbitany H.
   Plast Reconstr Surg. 2010 Sep;126(3):1121-2; author reply 1122. No abstract available.
   PMID: 20811255 [PubMed - indexed for MEDLINE]
   Related citations

2. AlloDerm performance in the setting of prosthetic breast surgery, infection, and irradiation.
   Newman MI, Hanabergh E, Samson MC.
   Plast Reconstr Surg. 2010 Sep;126(3):1120; author reply 1120-1. No abstract available.
   PMID: 20811254 [PubMed - indexed for MEDLINE]
   Related citations

3. Preventing the "Bottoming Out" and "Star-gazing" Phenomena in Inferior Pedicle Breast Reduction with an Acellular Dermal Matrix Internal Brassiere.
   Brown RH, Izaddoost S, Bullocks JM.
   Aesthetic Plast Surg. 2010 Jul 3. [Epub ahead of print]
   PMID: 20602099 [PubMed - as supplied by publisher]
   Related citations

4. The use of acellular dermal matrix in the correction of visible parasternal deformities after breast reconstruction.
   Uflacker AB, Janis JE.
   Plast Reconstr Surg. 2010 Jul;126(1):34e-36e. No abstract available.
   PMID: 20595842 [PubMed - indexed for MEDLINE]
   Related citations

5. The effect of acellular dermal matrix use on complication rates in tissue expander/implant breast reconstruction.
   Lanier ST, Wang ED, Chen JJ, Arora BP, Katz SM, Gelfand MA, Khan SU, Dagum AB, Bui DT.
   Ann Plast Surg. 2010 May;64(5):674-8.
   PMID: 20395795 [PubMed - indexed for MEDLINE]
   Related citations

6. Decreasing expander breast infection: A new drain care protocol.
   Murray JD, Elwood ET, Jones GE, Barrick R, Feng J.
   Can J Plast Surg. 2009 Spring;17(1):17-21.
   PMID: 20190908 [PubMed - in process] Free PMC Article Free text
   Related citations

NCBI Resources How To

PubMed.gov
U.S. National Library of Medicine
National Institutes of Health

Search: PubMed | RSS | Save search | Limits | Advanced search | Help

strattice | Search | Clear

Display Settings: Summary, Sorted by Recently Added

Results: 3

1. Histological appearance of Strattice(TM) tissue matrix used in breast reconstruction.
   Katerinaki E, Zanetto U, Sterne GD.
   J Plast Reconstr Aesthet Surg. 2010 Jul 20. [Epub ahead of print] No abstract available.
   PMID: 20650694 [PubMed - as supplied by publisher]
   Related citations

2. Laparoscopic repair of potentially contaminated abdominal ventral hernias using a xenograft: a case series.
   Parra MW, Rodas EB, Niravel AA.
   Hernia. 2010 Jun 11. [Epub ahead of print]
   PMID: 20544369 [PubMed - as supplied by publisher]
   Related citations

3. Activation of human mononuclear cells by porcine biologic meshes in vitro.
   Orenstein SB, Qiao Y, Klueh U, Kreutzer DL, Novitsky YW.
   Hernia. 2010 Aug;14(4):401-7. Epub 2010 Feb 10.
   PMID: 20145965 [PubMed - in process]
   Related citations

Display Settings: Summary, Sorted by Recently Added

Vivantes

AGO ARBEITSGEMEINSCHAFT GYNÄKOLOGISCHE ONKOLOGIE E.V.

MAMMA

Guidelines Breast
Version 2010.1.1D

Rekonstruktion mit Implantaten nach MX Erwägungen

	Oxford / AGO LoE	GR
➢ Kostengünstig		
➢ Bilaterales Vorgehen kann kosmetisches Ergebnis verbessern		
➢ Symmetrie in Form und Volumen mit Permanent-Expandern leichter zu erreichen		
➢ Altersunabhängig	3b	C +/-
➢ Partiell submuskuläre Implantattasche kombiniert mit Netz oder azellulärer Dermis (ADM) optimiert die Implantatabdeckung	2b	B +
➢ Lipofilling kann hilfreich sein	3b	C +/-
➢ Sofortrekonstruktion hat höhere Komplikationsrate	2b	B

FORSCHEN
LEHREN
HEILEN

Vivantes

Moderne Brustchirurgie: Von der Ästhetik bis zur Rekonstruktion

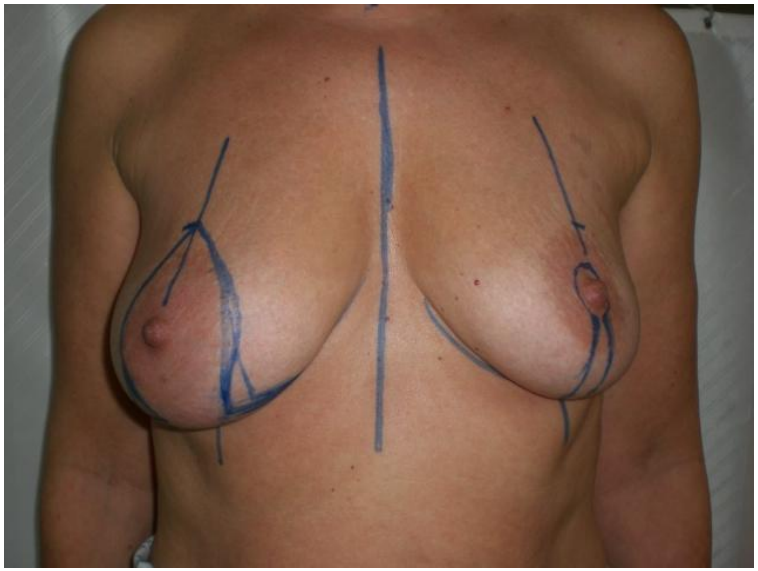

(TiLoop™)

Vivantes

Moderne Brustchirurgie: Von der Ästhetik bis zur Rekonstruktion

DCIS mit 7 cm Ausdehnung li. oben außen

Sofortrekonstruktion mit Implantat und (TiLoop Bra™)

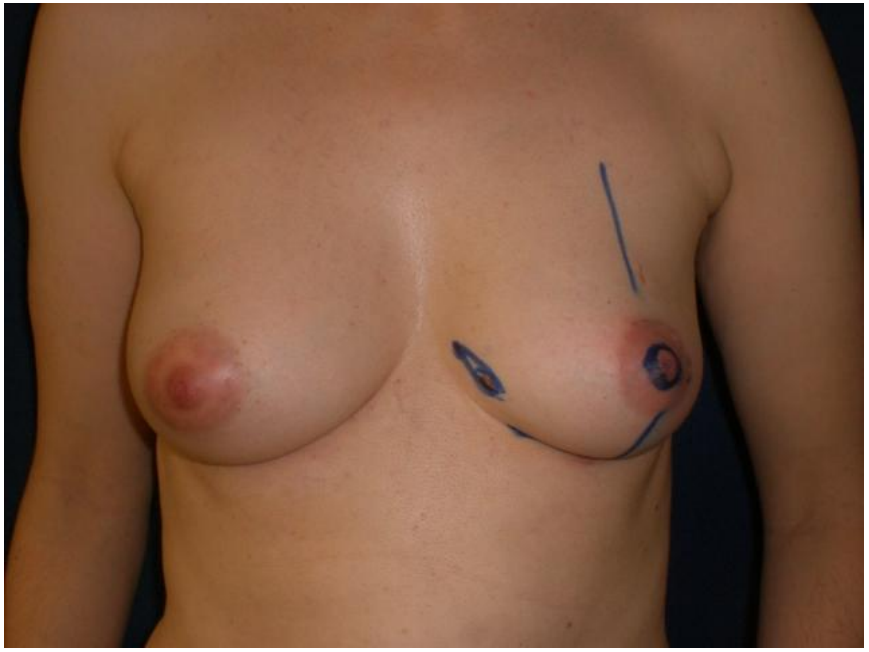

Vivantes

Azelluläre Dermis

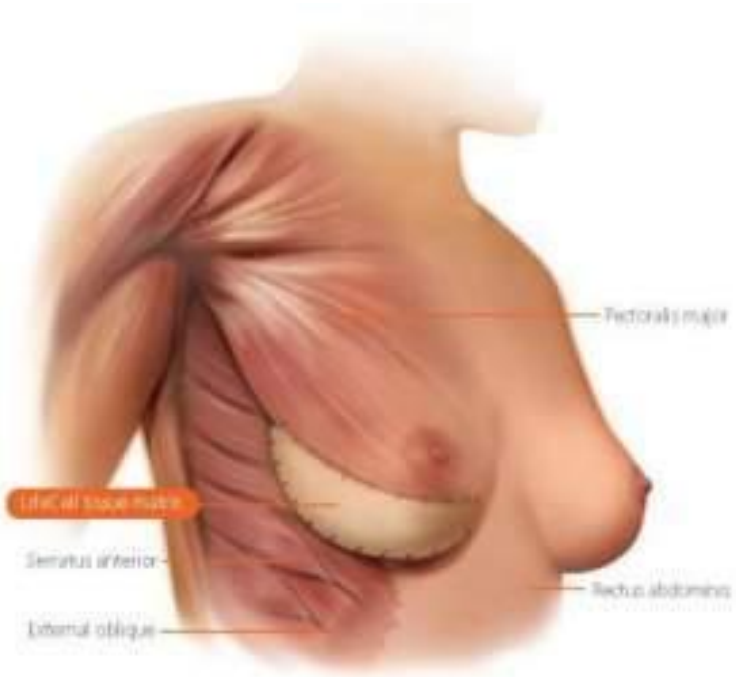

Vivantes

Moderne Brustchirurgie: Von der Ästhetik bis zur Rekonstruktion

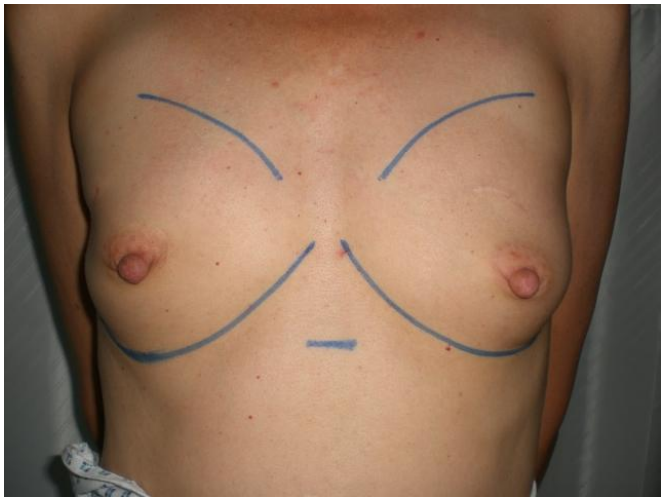

Vivantes

Arch Gynecol Obstet (2005) 273: 79–85
DOI 10.1007/s00404-005-0026-x

ORIGINAL ARTICLE

Wulf Siggelkow · Antje Lebrecht · Heinz Kölbl
Andre Faridi

Dual-plane implant positioning for capsular contracture of the breast in combination with mastopexy

Es geht auch ohne Netz …

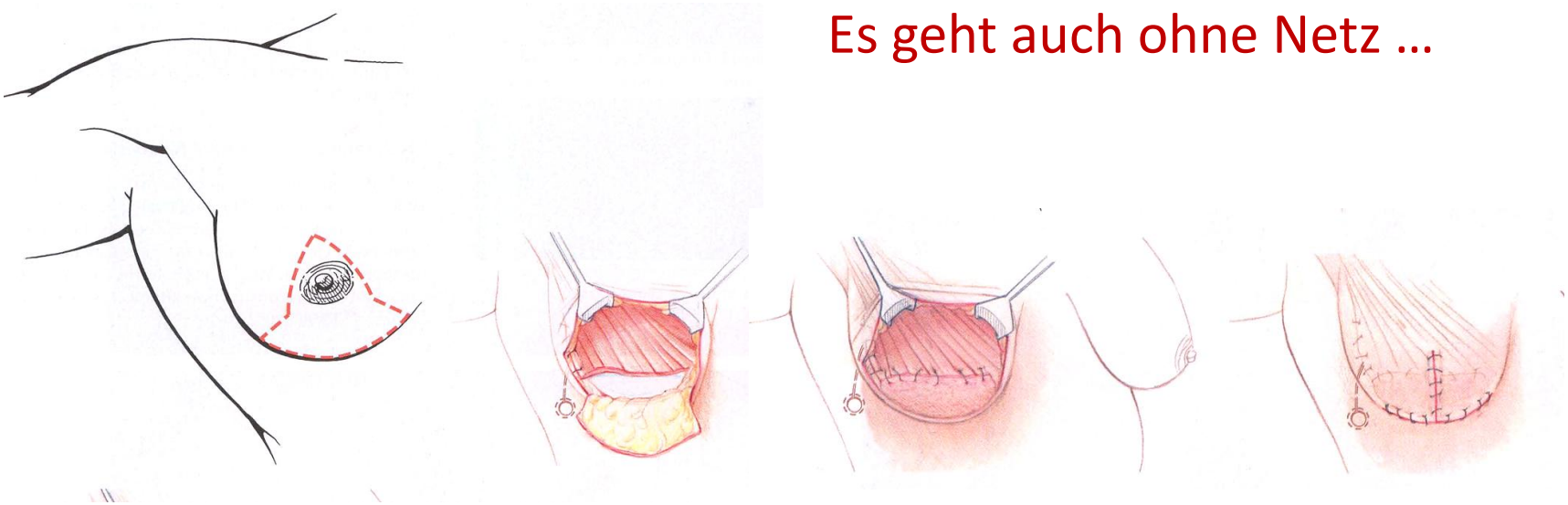

Vivantes

Moderne Brustchirurgie: Von der Ästhetik bis zur Rekonstruktion

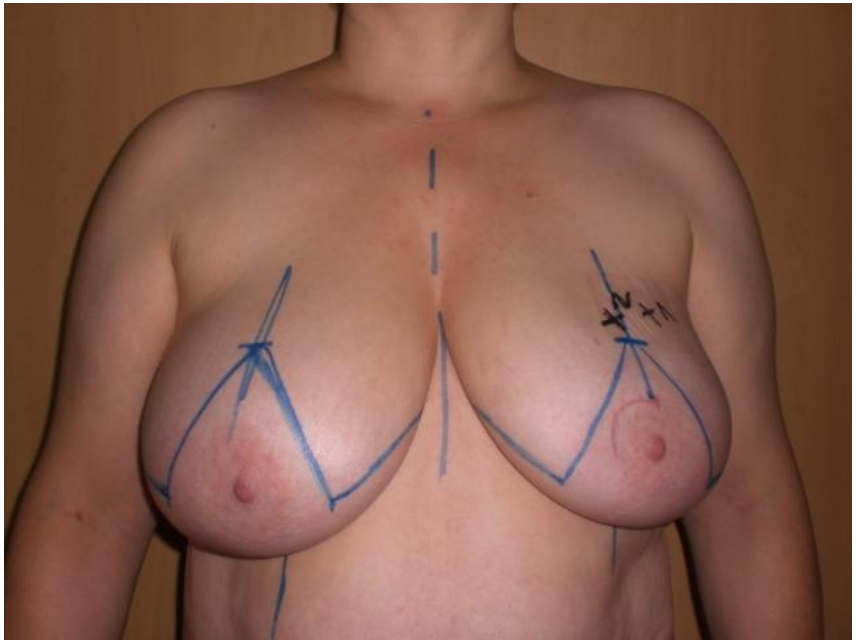

DCIS li.
> 6 cm

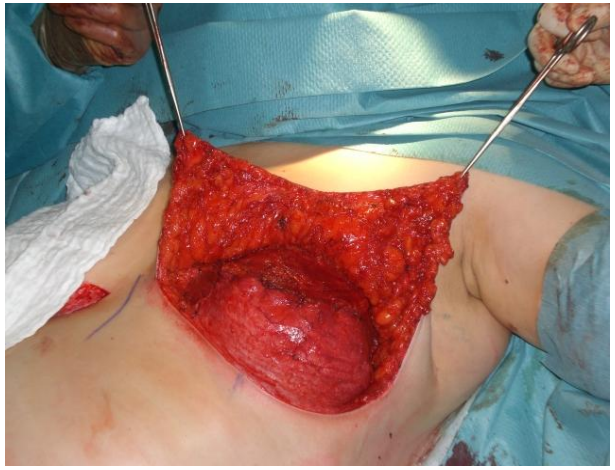

SNB und
dual-plane
Implantatrekonstruktion
angl. Reduktion re.

Vivantes

Moderne Brustchirurgie: Von der Ästhetik bis zur Rekonstruktion

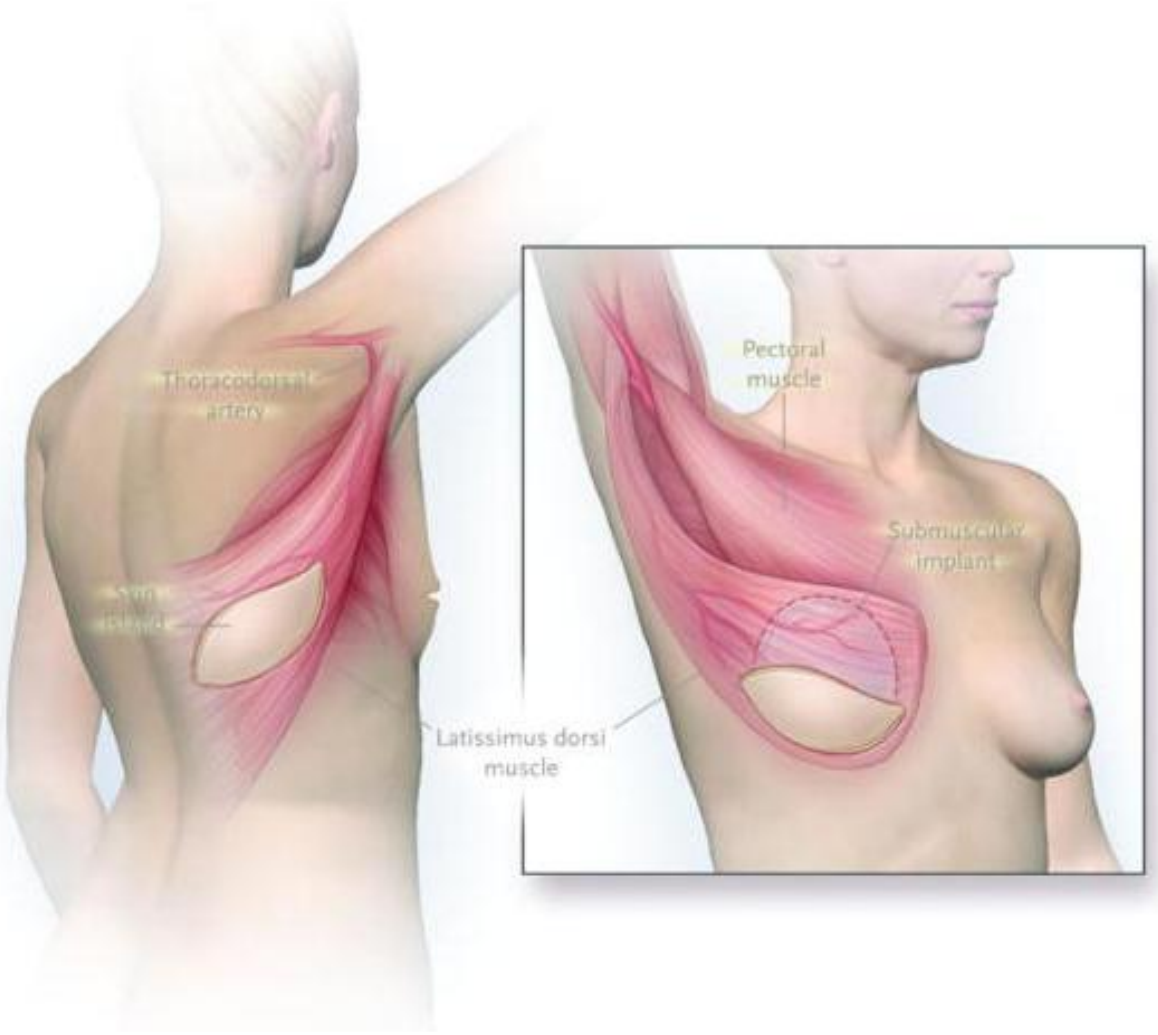

Vivantes

Sekundäre Brustrekonstruktion mit einem LDF

Moderne Brustchirurgie: Von der Ästhetik bis zur Rekonstruktion

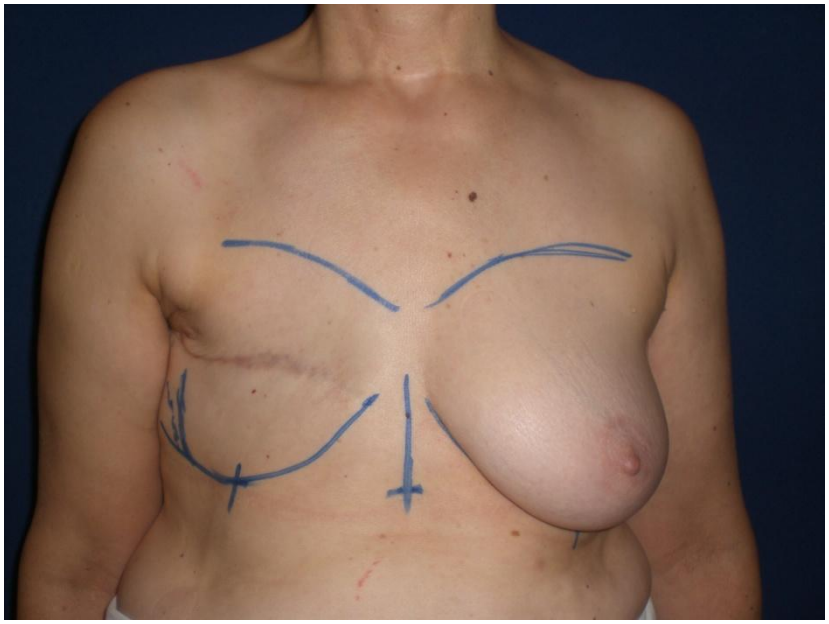

Vivantes

Moderne Brustchirurgie: Von der Ästhetik bis zur Rekonstruktion

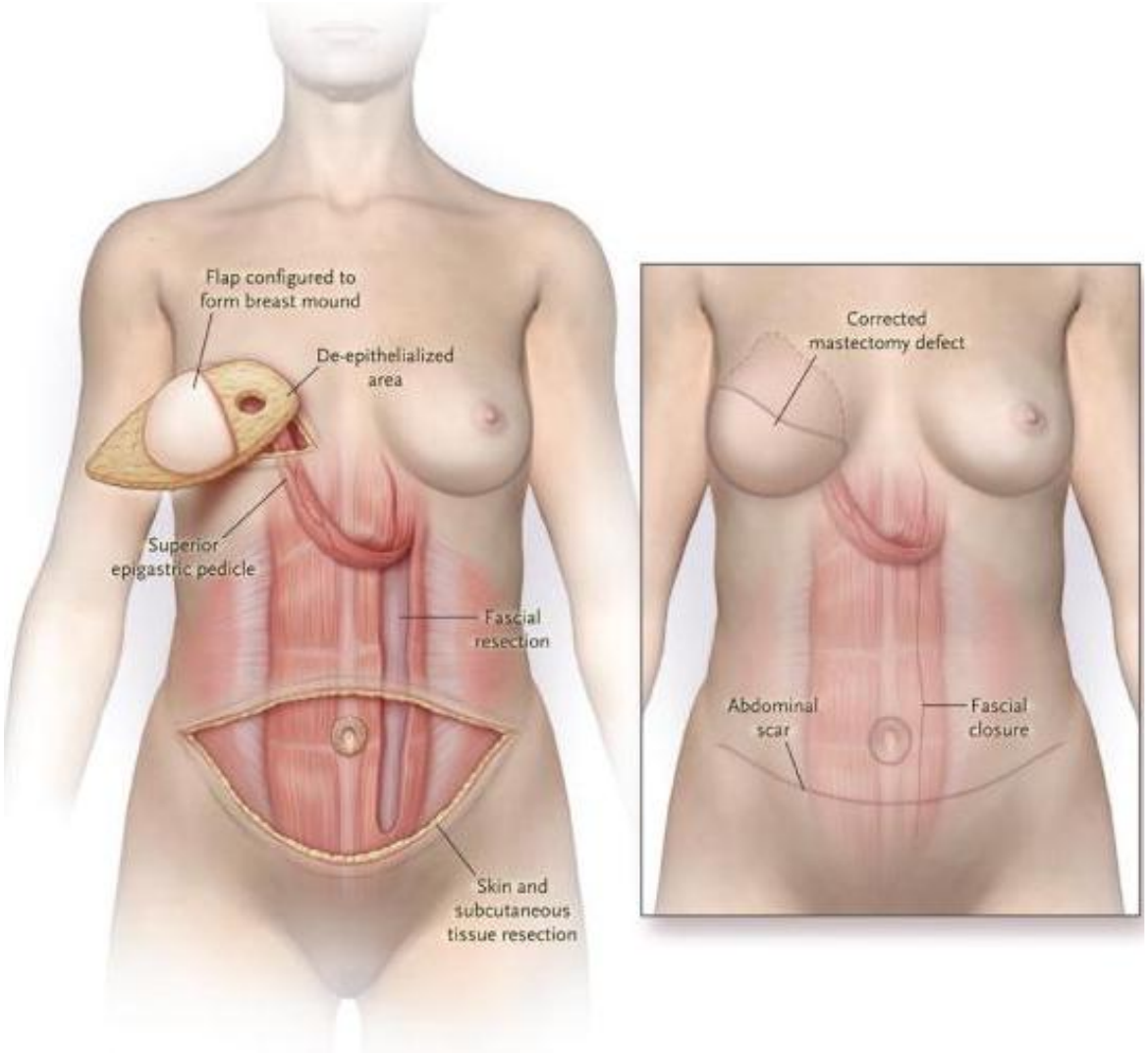

Vivantes

Moderne Brustchirurgie: Von der Ästhetik bis zur Rekonstruktion

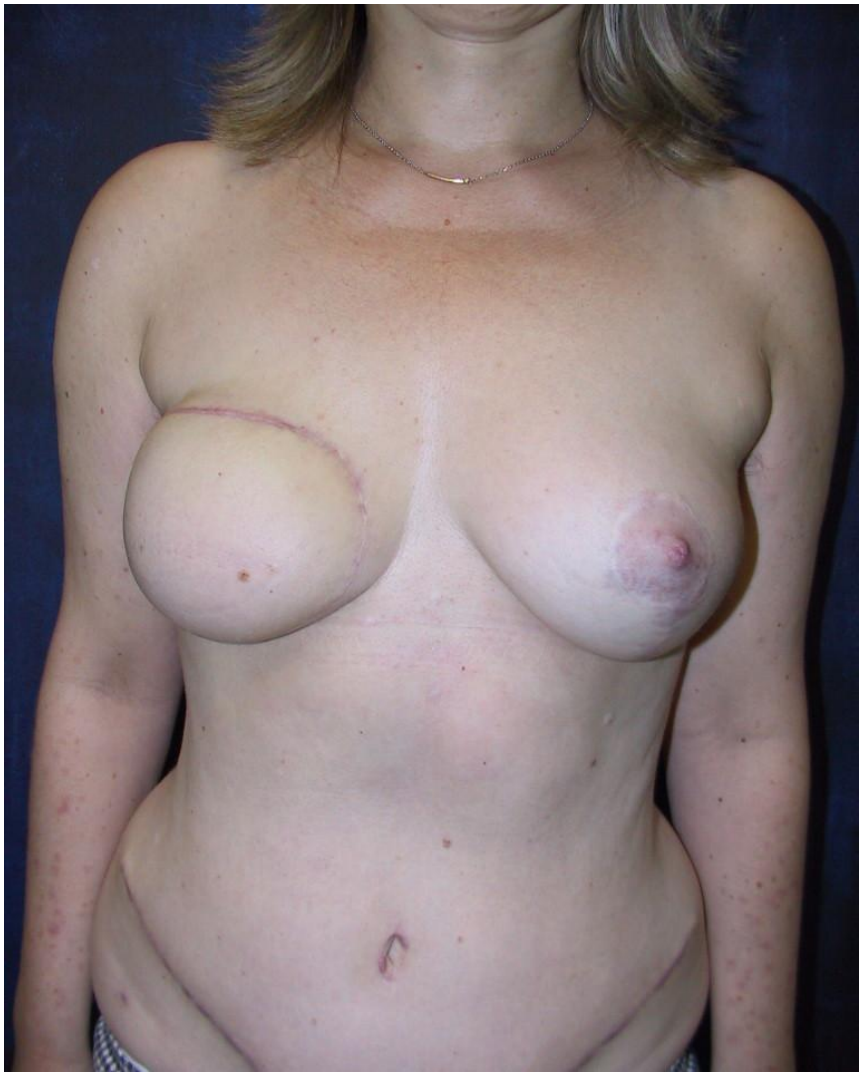

Vivantes

Moderne Brustchirurgie: Von der Ästhetik bis zur Rekonstruktion

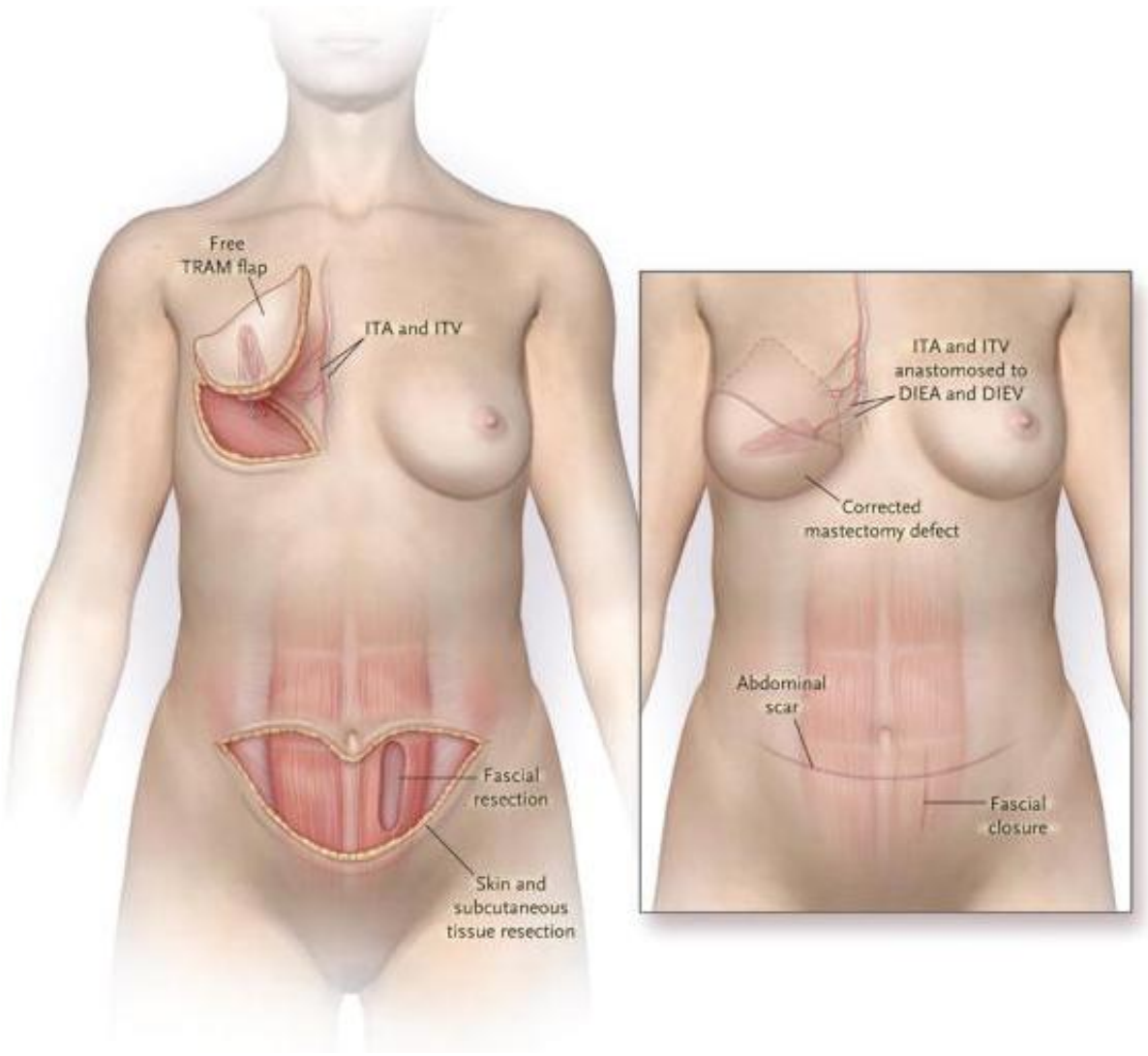

Vivantes

Moderne Brustchirurgie: Von der Ästhetik bis zur Rekonstruktion

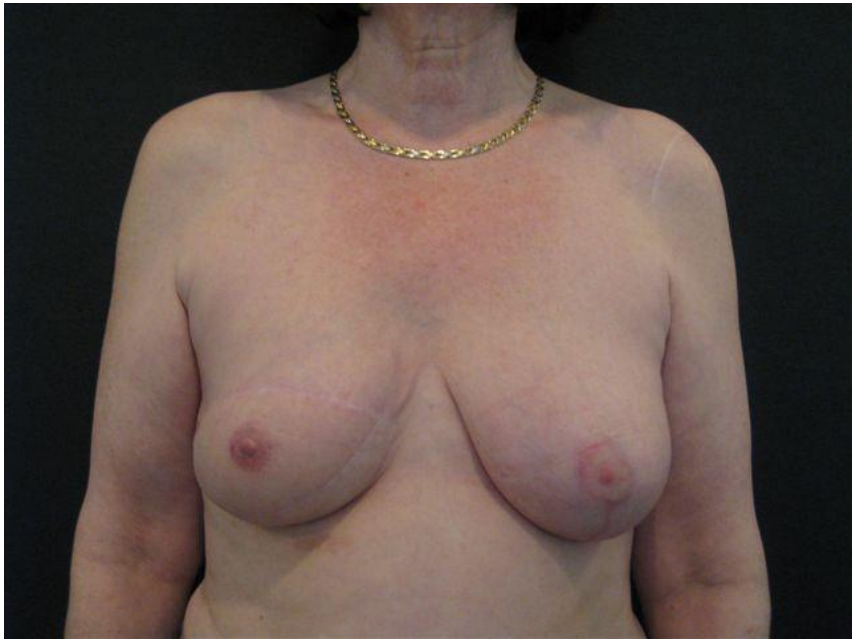

Vivantes

Mammahypertrophie / Makromastie

- Reduktionsplastik
- Mastopexie

Mammahypoplasie / Mikromastie

- Augmentationsplastik

Angeborene Fehlbildungen

- Anisomastie / Asymmetrie
- Poland-Syndrom
- Tubuläre / tuburöse Brust

A. Faridi
Gynäkologie und Gynäkologische Onkologie, Asklepios Brustzentrum, Hamburg

Möglichkeiten der Mamma-Reduktionsplastik

Gynäkologe 2008 · 41:961–970

Tab. 1 Aufklärungsinhalte
Empfindungs- und Durchblutungsstörungen der Brustwarzen – Absterben der Brustwarzen (Nekrose) – Verminderte oder verstärkte Sensibilität
Asymmetrie
Narbenkeloide
Schmerzen
Notwendigkeit einer Korrekturoperation
Verlust der Stillfähigkeit (abhängig von der Methode)
Erneute Hypertrophie / Ptose (u. a. nach Schwangerschaft und Stillzeit)

Moderne Brustchirurgie: Von der Ästhetik bis zur Rekonstruktion

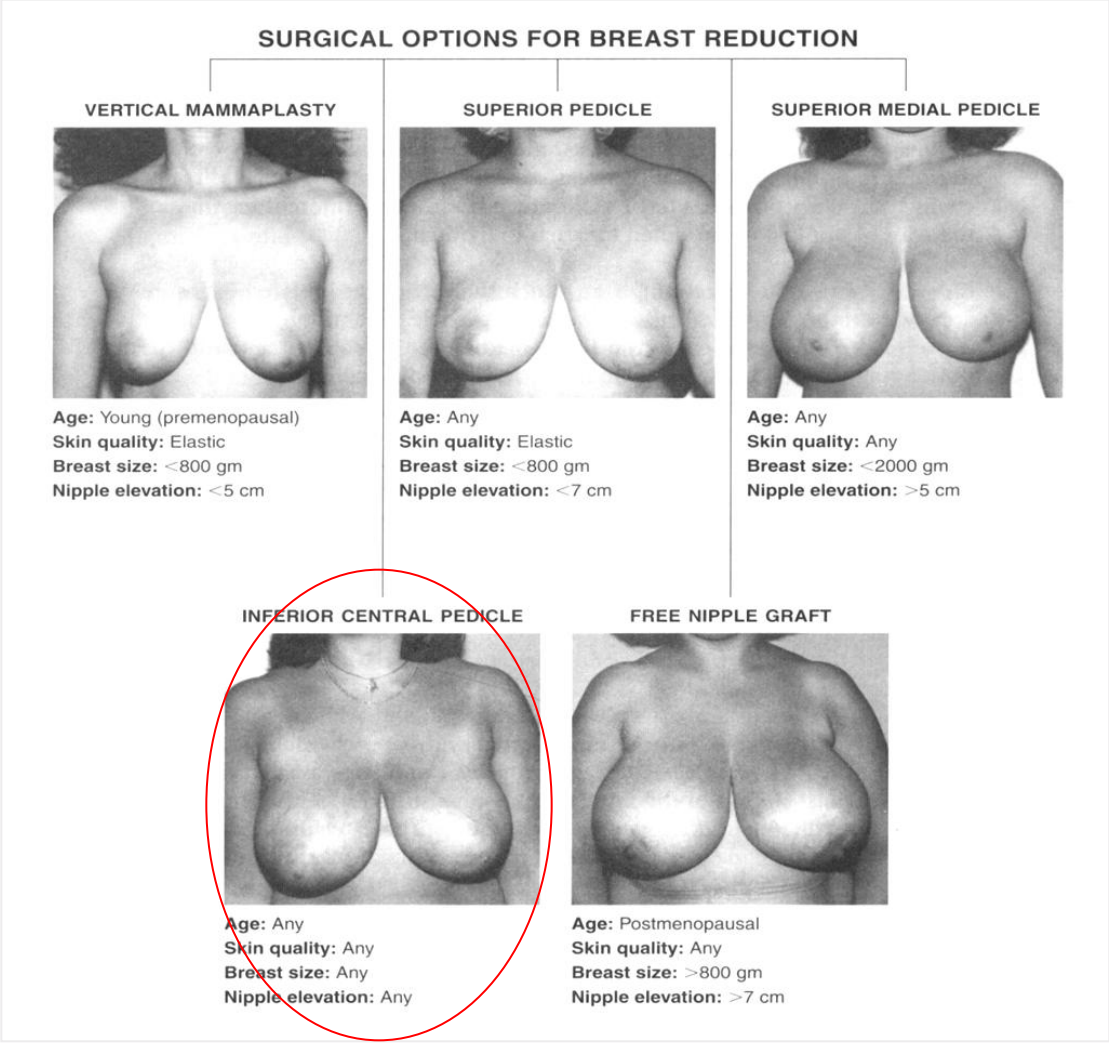

Vivantes

Moderne Brustchirurgie: Von der Ästhetik bis zur Rekonstruktion

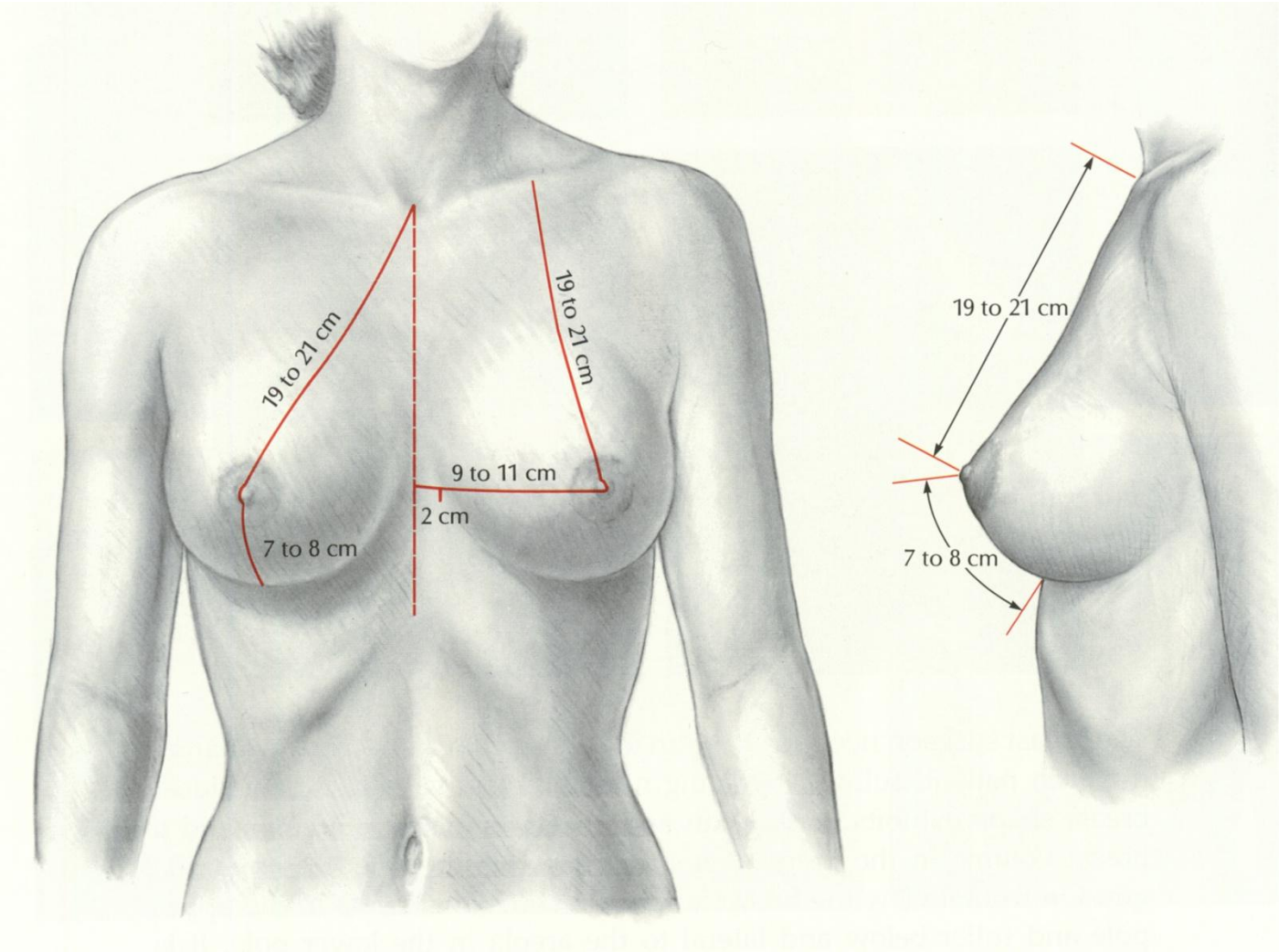

Vivantes

Moderne Brustchirurgie: Von der Ästhetik bis zur Rekonstruktion

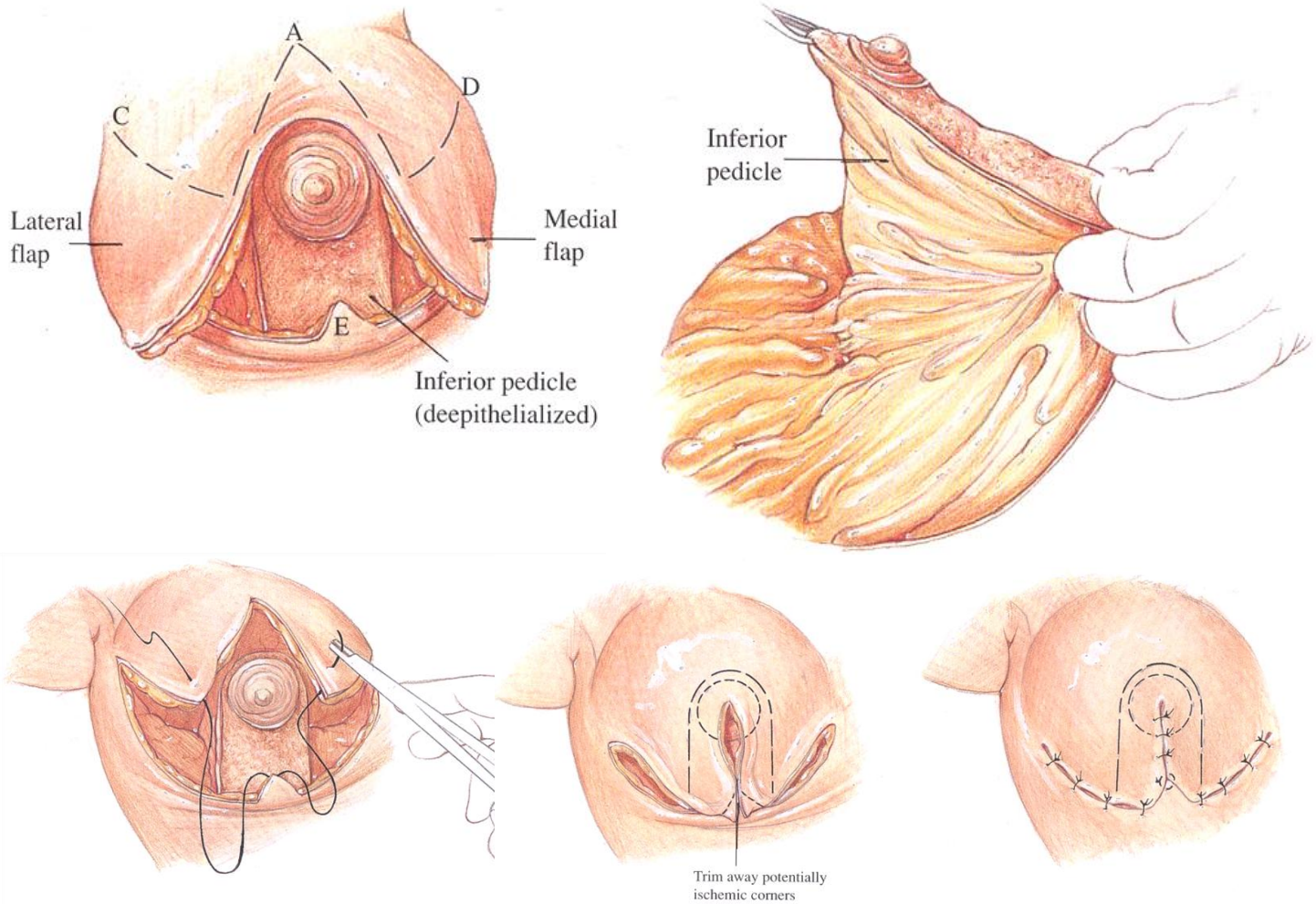

Hoffman S. Inferior pedicle technique in breast reduction in Spear SL: Surgery of the breast, 2e. Lippincott, 2006.

Vivantes

Reduktionsplastik mit modifizierter inferiorer Technik und kranialer Stielung des MAK

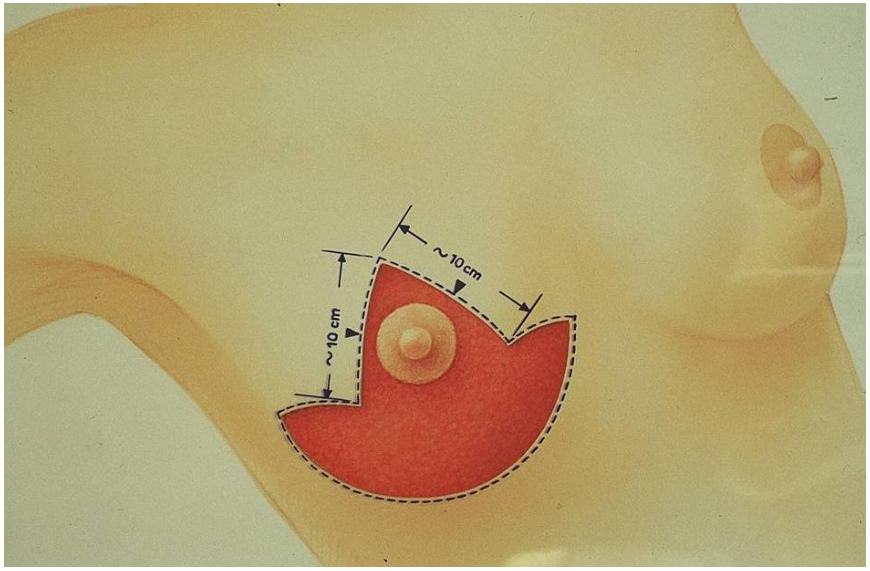

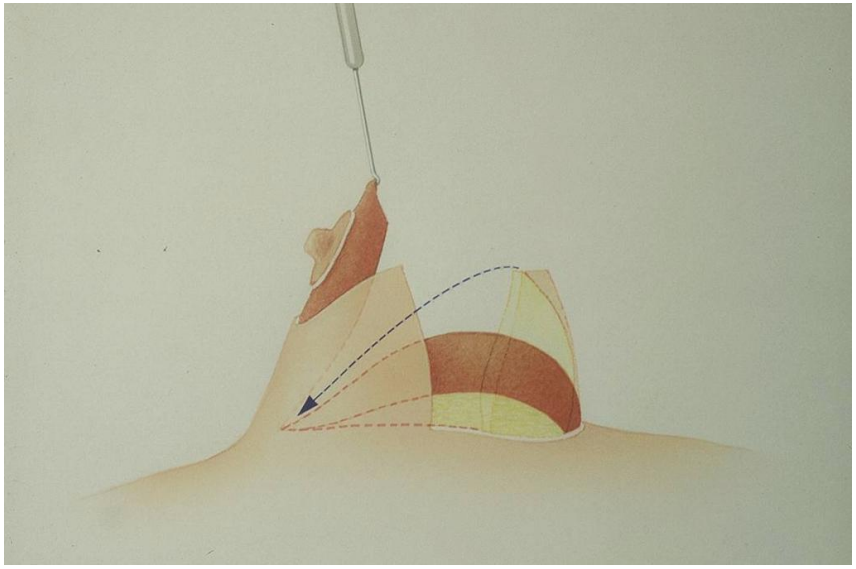

Moderne Brustchirurgie: Von der Ästhetik bis zur Rekonstruktion

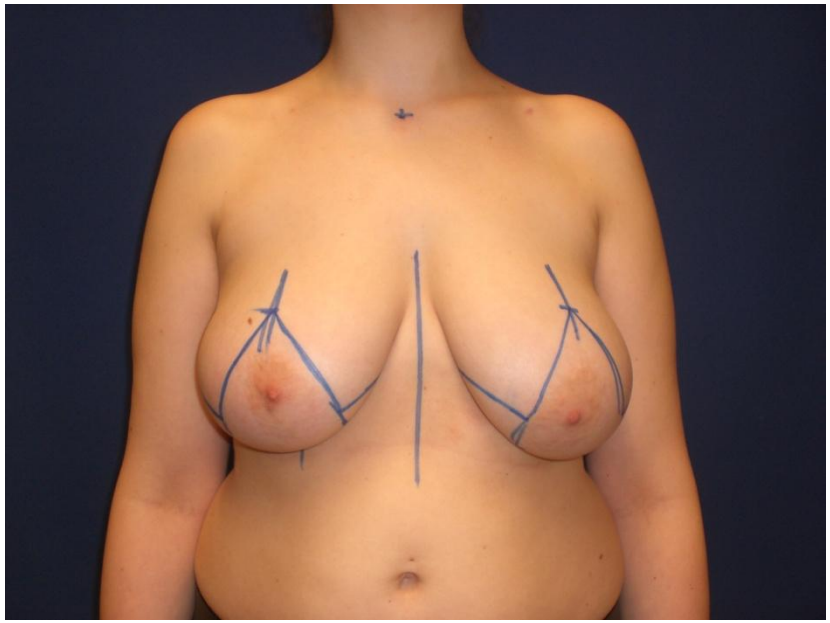

Vivantes

Moderne Brustchirurgie: Von der Ästhetik bis zur Rekonstruktion

Resektionsgewichte
250 g je Seite

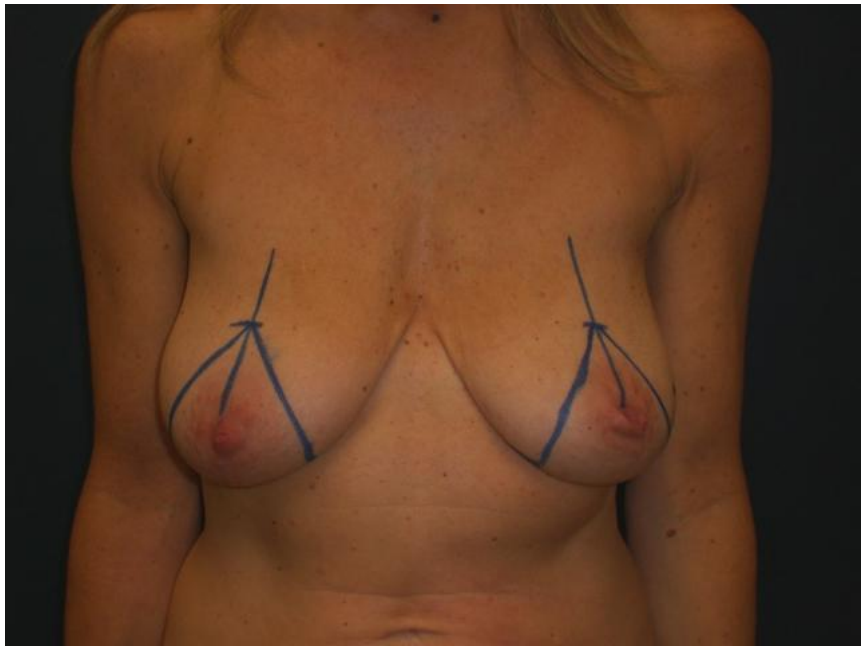

Vivantes

Ptosisprophylaxe

durch Überkorrektur

Moderne Brustchirurgie: Von der Ästhetik bis zur Rekonstruktion

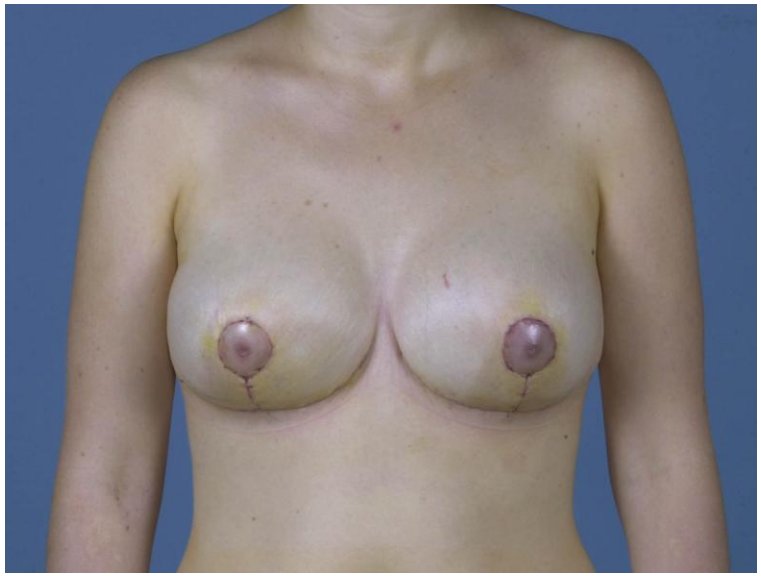

Resektionsgewichte
350 g / 400 g

Vivantes

Moderne Brustchirurgie: Von der Ästhetik bis zur Rekonstruktion

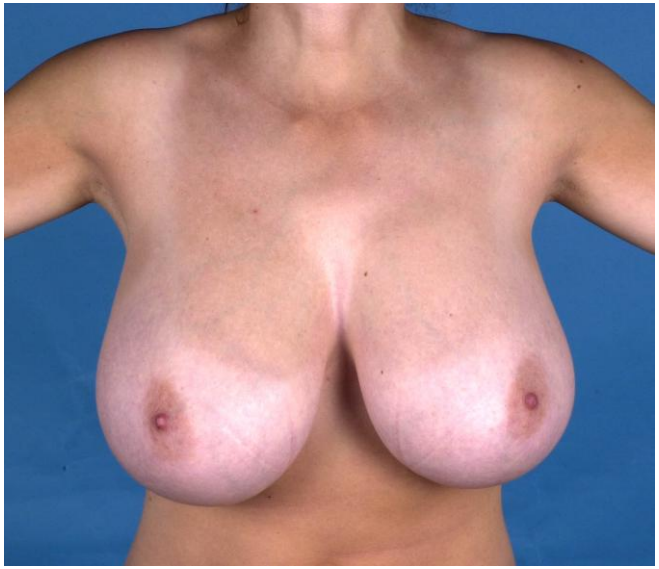

Reduktionsplastik

Resektionsgewichte
1250 g / 1150 g

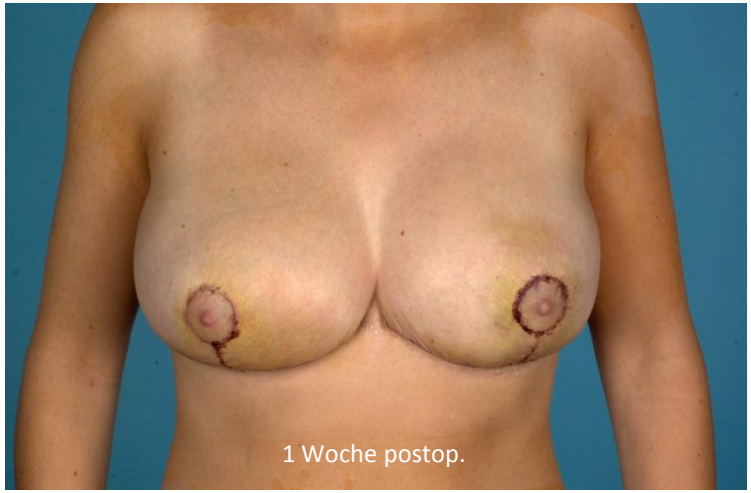

1 Woche postop.

3 Jahre postop.

6 Jahre postop.

Vivantes

Moderne Brustchirurgie: Von der Ästhetik bis zur Rekonstruktion

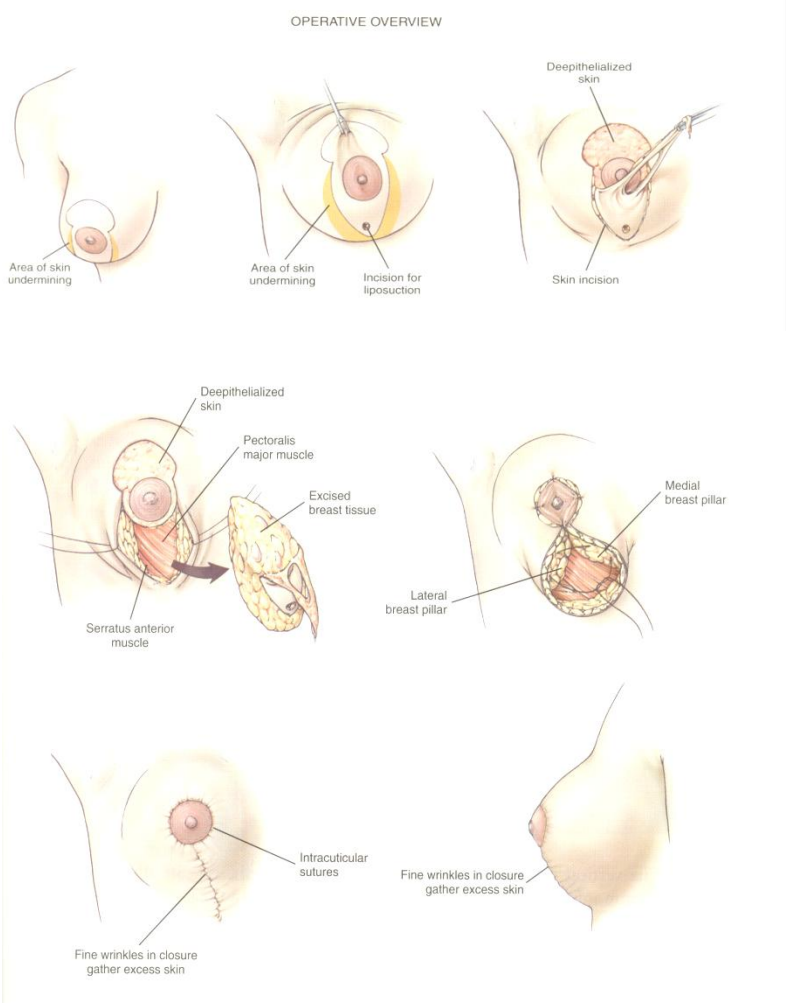

Lejour M.

Vertical mammaplasty and liposuction of the breast.

Plast Reconstr Surg 94: 100, 1994

Lassus C.

A technique of breast reduction.

Int Surg 53: 69, 1970

Vivantes

Resektionsgewichte
500 g / 480 g

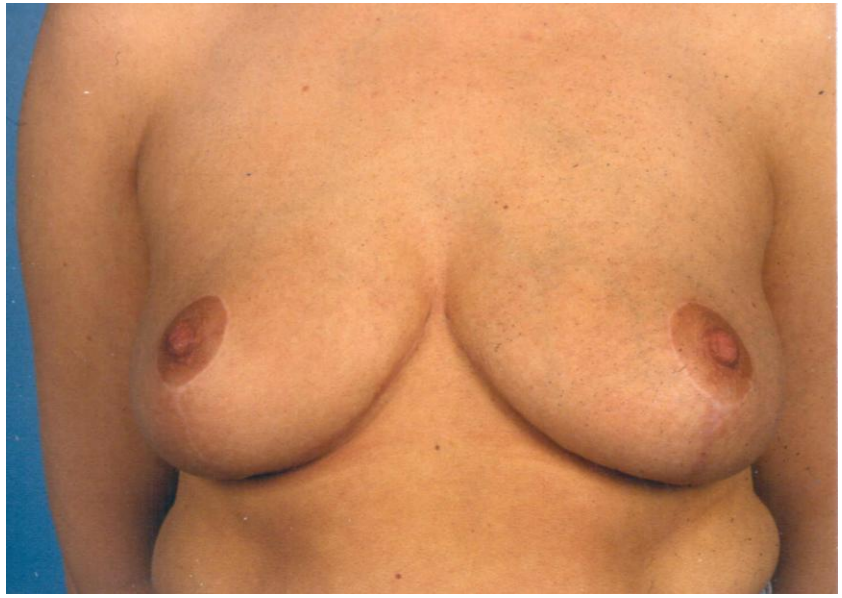

Moderne Brustchirurgie: Von der Ästhetik bis zur Rekonstruktion

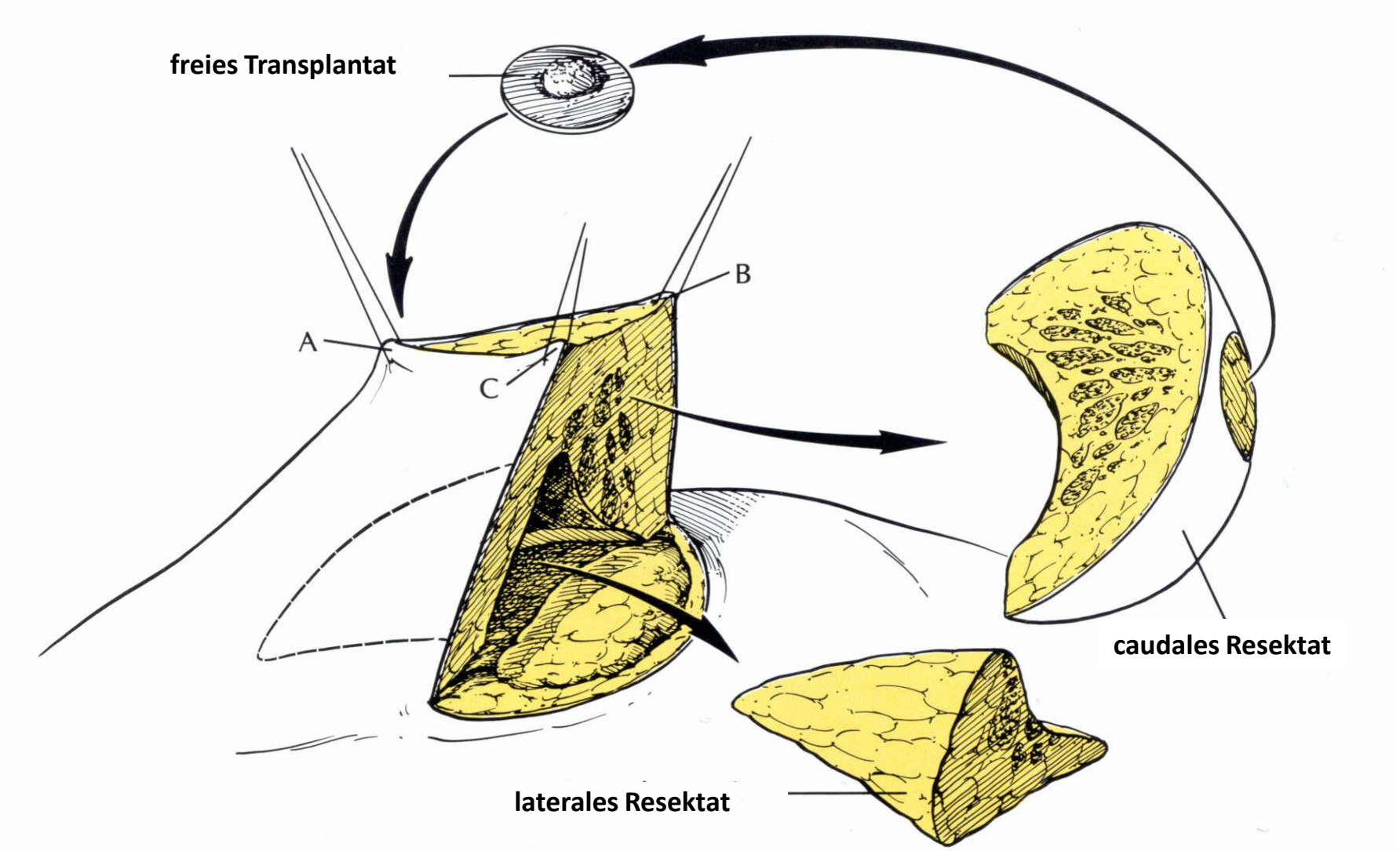

Vivantes

Resektionsgewichte
1800 g / 1950 g

A. Faridi
Gynäkologie und Gynäkologische Onkologie, Asklepios Brustzentrum, Hamburg

Möglichkeiten der Mamma-Reduktionsplastik

Gynäkologe 2008 · 41:961–970

38. Strittmatter H, Buchen S, Faridi A (2008) Ist die Reduktionsplastik mit zentralem und/oder inferiorem Stiel eine sichere und variationsreiche Operationstechnik? Geburtsh Frauenheilkd 68: 497–504

Tab. 3 Komplikationen bezogen auf Zahl der reduzierten Mammae

Komplikationen	Strittmatter et al. [38] n = 130		Schnur et al. [36] n = 719		Heilenkötter et al. [19] n = 742		Menderes et al. [27] n = 121		Lejour [25] n = 283		O'Grady et al. [30] n = 266	
	(n)	(%)	(n)	(%)	(n)	(%)	(n)	(%)	(n)	(%)	(n)	(%)
Mamillennekrose												
Total	1	0,5			4	0,6	1	0,8			1	0,4
Partiell	1	0,5	2	0,3	13	1,8	2	1,6	2	0,7		
Fettgewebsnekrose	2	0,9	12	1,7	9	1,3	4	3,3	4	1,4	4	1,5
Stegnekrose	1	0,5			21	3,0						
Serome	0		5	0,7					14	4,9	0	
Hämatome	0				2	0,3	2	1,6	3	1,1	11	4,1
Wundinfektion	3	1,3	6	0,8	2	0,3	5	4,1	1	0,4	9	3,4
Nahtdehiszenz	2	0,9							4	1,4	23	8,6
gesamt	10	4,5	25	3,5	53	7,5	14	11,5	28	9,9	48	18

Vivantes

Die Reduktionsplastik mit umgekehrt T-förmiger Narbe

(modifizierte) inferiore/zentrale Technik

Vorteile

- Freihandanzeichnung
- Für fast alle Formen der Mammahypertrophie geeignet
- Festlegung der Mamillenposition am Ende der Operation
- Individuelle Gestaltung der Brustform
- Als brusterhaltende Technik (BET) geeignet *alle vier Quadranten zugänglich*
- Stillfähigkeit bleibt in vielen Fällen erhalten
- Modifikationen mit kranialer, zentraler oder inferiorer Stielung
- Modifikationen mit verchiedenen Narbenverläufen *(z.B. short-scar-Technik)*

Nachteile

- T - förmiger Narbenverlauf

  Narben können allerdings individuell kurz gehalten werden

A Comparison of Complication Rates in Large and Small Inferior Pedicle Reduction Mammaplasty

Plast. Reconstr. Surg. 115: 736, 2005

Kevin F. O'Grady, B.A.Sc., M.H.Sc., M.D., Achilleas Thoma, M.D., M.Sc., and Arianna Dal Cin, B.Sc., M.D.
Hamilton, Ontario, Canada

Summary

This study demonstrated that the inferior pedicle technique breast reduction is a safe technique for both large and small reductions. Certainly, it can be used without hesitation in reductions up to approximately 1310 g per breast without a significant increase in any of the major and common complications of this operation. Reductions greater than 1000 g of tissue removed per side do result in an increase in wound dehiscence.

Moderne Brustchirurgie: Von der Ästhetik bis zur Rekonstruktion

Purse-string Reduktionsplastik (!?) 2 Jahre zuvor (110 g je Seite)

Vivantes

Moderne Brustchirurgie: Von der Ästhetik bis zur Rekonstruktion

Vivantes

Mammahypertrophie / Makromastie

- Reduktionsplastik
- Mastopexie

Mammahypoplasie / Mikromastie

- Augmentationsplastik

Angeborene Fehlbildungen

- Anisomastie / Asymmetrie
- Poland-Syndrom
- Tubuläre / tuburöse Brust

Moderne Brustchirurgie: Von der Ästhetik bis zur Rekonstruktion

Die Verbreiterung der Brustbasis läßt die Hüftregion schmaler erscheinen

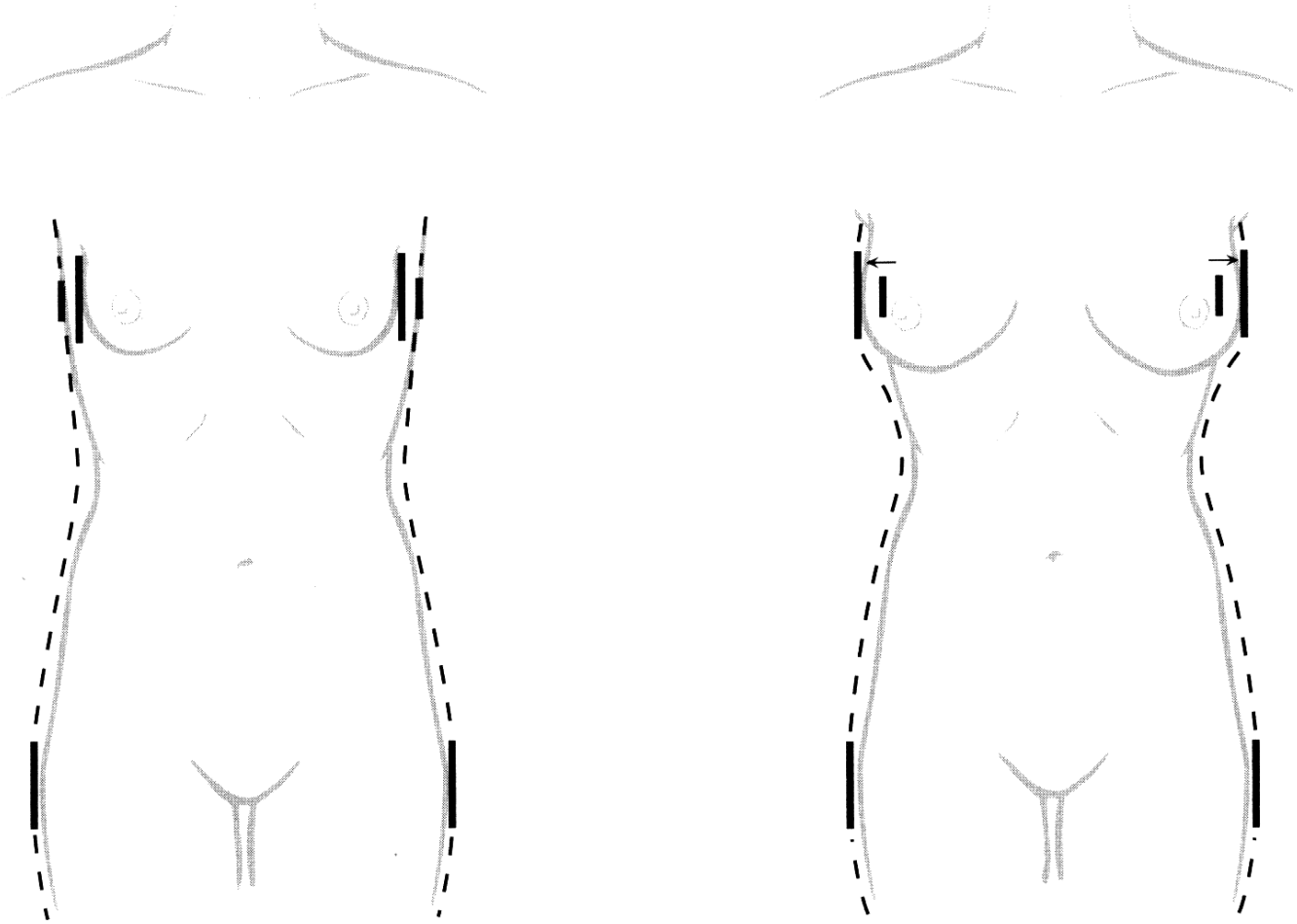

Zu beachten sind folgende **Grundsätzte**:

- Erwartungen der Patientin genau erfragen
- realistische Ziele formulieren
- sorgfältige Selektion der Patienten für die jeweilige Methode
- umfassende Aufklärung über Vor- und Nachteile
- Erläuterung von alternativen Methoden
- ggf. Hinzuziehung eines versierten Operteurs bzw. Überweisung

Die Kapselfibrose ist mit mind. 25% die häufigste Komplikation und in vielen Fällen verbunden mit Schmerzen

Moderne Brustchirurgie: Von der Ästhetik bis zur Rekonstruktion

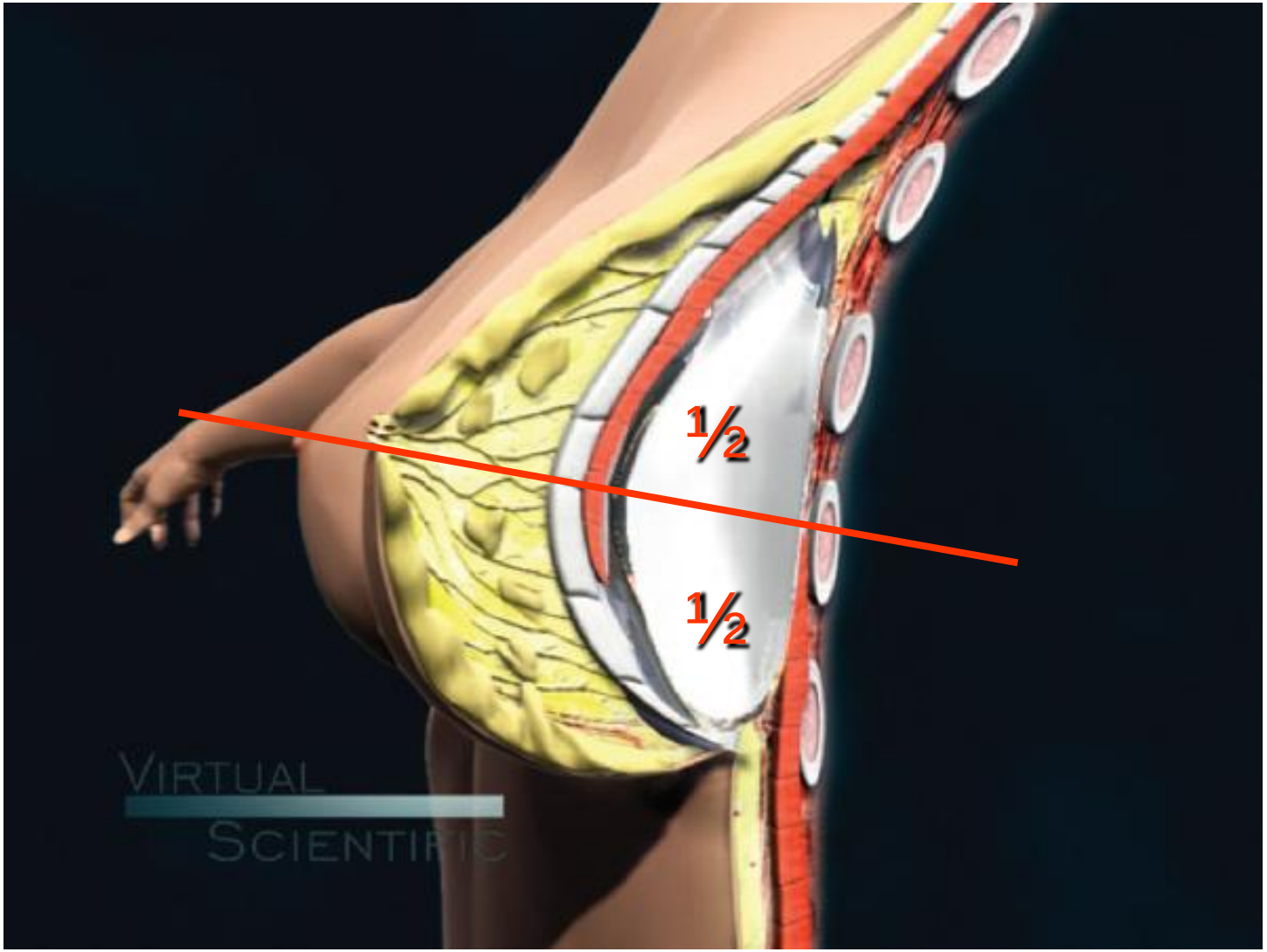

Vivantes

Implantatauswahl

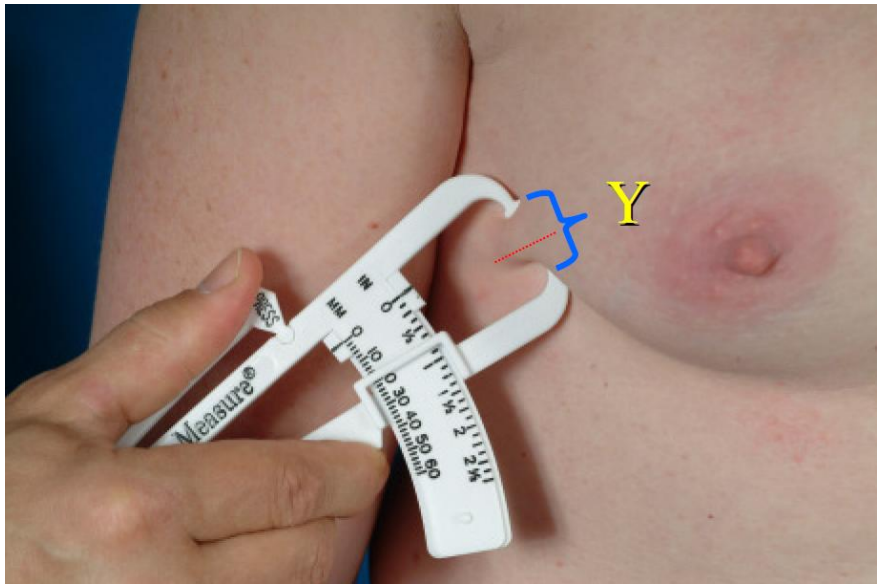

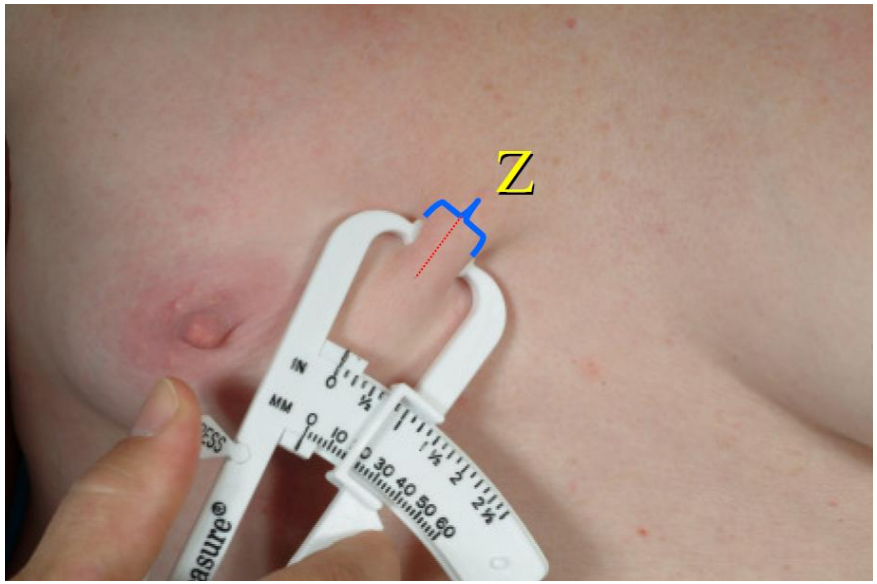

Measure lateral skin fold (Y)

Mesasure medial skin fold (Z)

Implantatauswahl

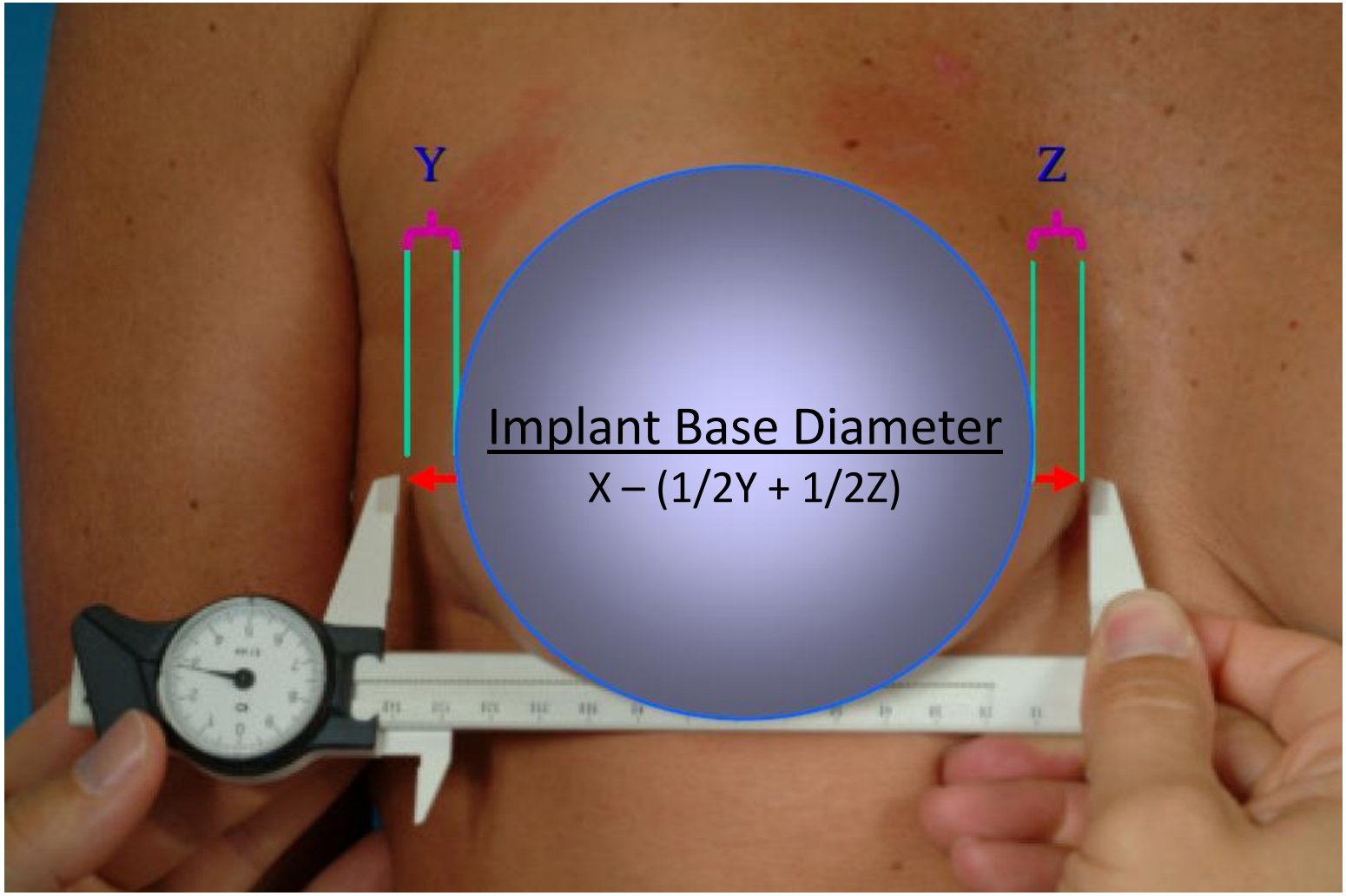

Moderne Brustchirurgie: Von der Ästhetik bis zur Rekonstruktion

245 g

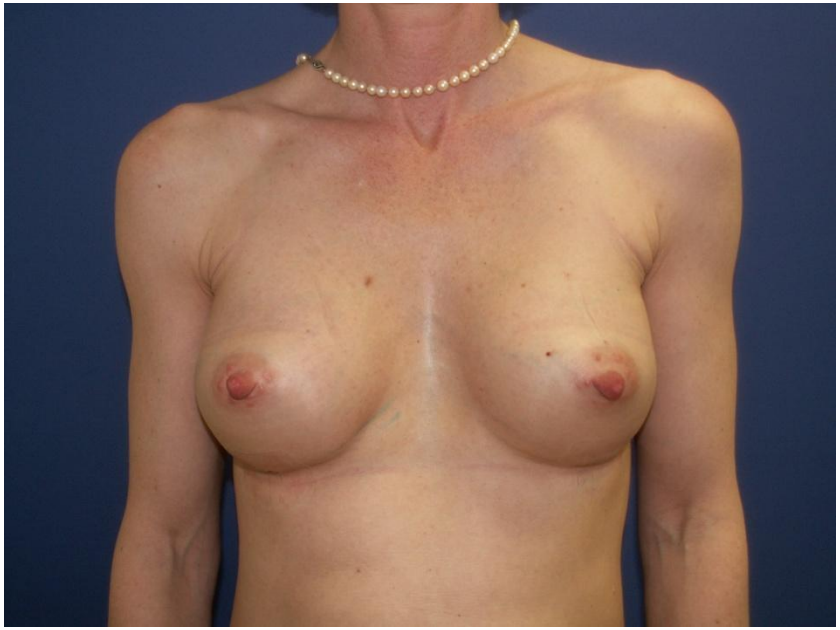

Vivantes

Mammahypertrophie / Makromastie

- Reduktionsplastik
- Mastopexie

Mammahypoplasie / Mikromastie

- Augmentationsplastik

Angeborene Fehlbildungen

- Anisomastie / Asymmetrie
- Poland-Syndrom
- Tubuläre / tuburöse Brust

Circumareolar Dermo-Glandular Plication: A New Concept for Correction Breast Ptosis

Aesth. Plast. Surg. 25:404–420, 2001

Ulrich T. Hinderer, M.D., Ph.D.

Clinica Mirasierra, Calle de la Masó, 83 28034 Madrid, Spain

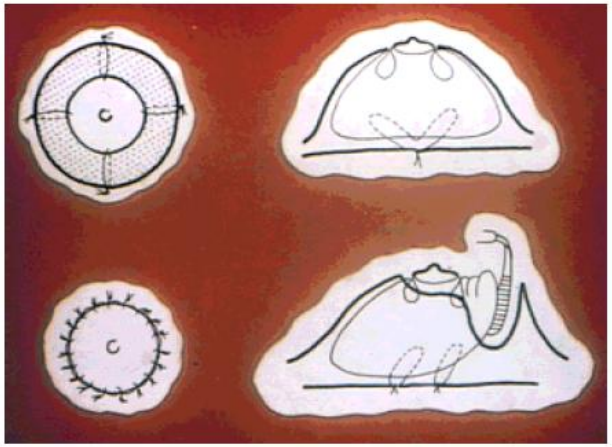

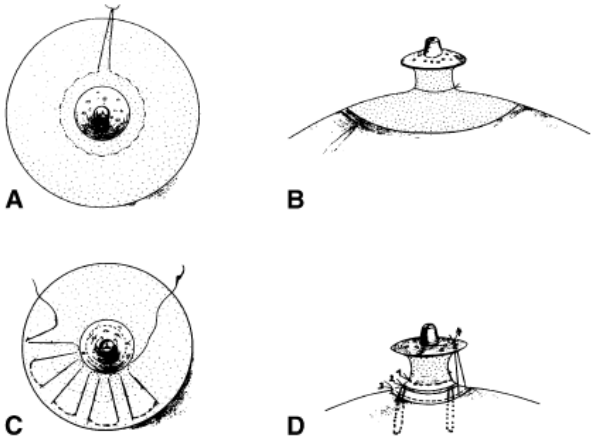

Gonzales-Ulloa M: Correction of hypotrophy of the breast by exogenous material. *Plast Reconstr Surg* **25**:15, 1960

Regnault P: The hypoplastic and ptotic breast: A combined operation with prosthetic augmentation. *Plast Reconstr Surg* **37**:31, 1966

Hinderer UT: Primera experiencia con una nueva técnica de mastoplastia para ptósis ligeras. In: VI Reunión Nacional de la Sociedad Española de Cirugía Plástica y Reparadora. Noticias Médicas, p. 26, 1969

Hinderer UT: Reduction and augmentation mammaplasty: remodelling mammaplasty with superficial and retromammary mastopexy. *Internat Micr Jour Aesth Plast Surg* 1972-E

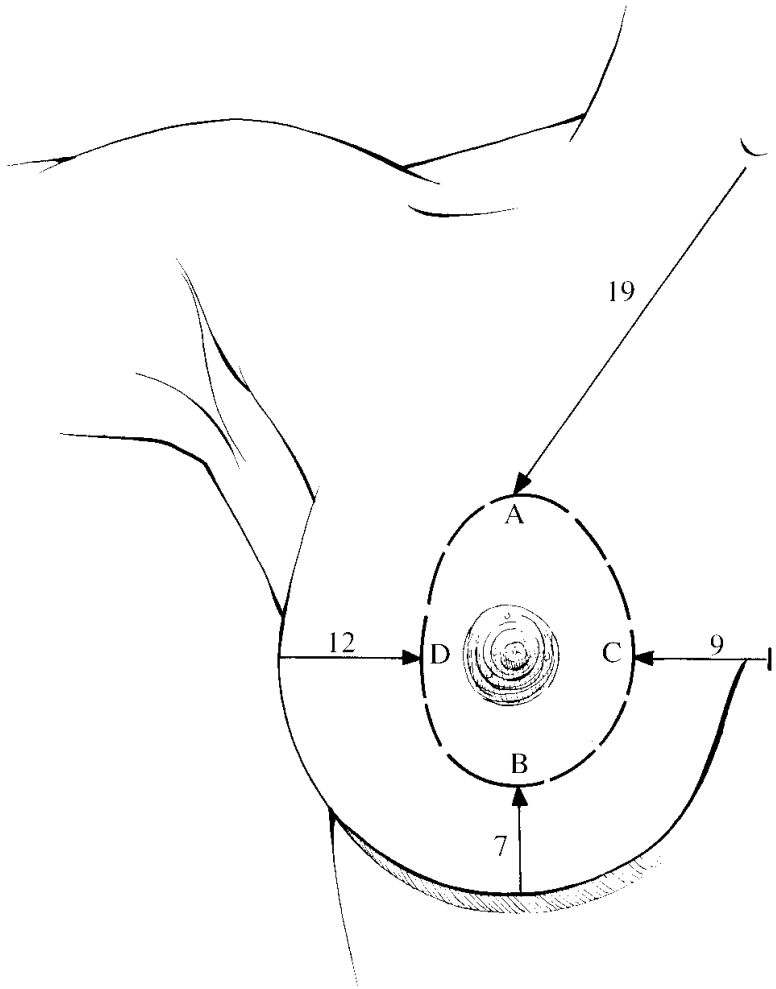

Benelli L.
A new periareolar mammaplasty: Round block technique.
Aesthetic Plast Surg. 14 (1990) 93

Moderne Brustchirurgie: Von der Ästhetik bis zur Rekonstruktion

Vivantes

Tubuläre Fehlbildung (snoopy nose deformity)

- Hernienartige Vorwölbung des BDK in die Areola
- Konstriktive Submammarfalte
- Hypoplasie der unteren (und oberen) Quadranten des BDK
- Anisomastie

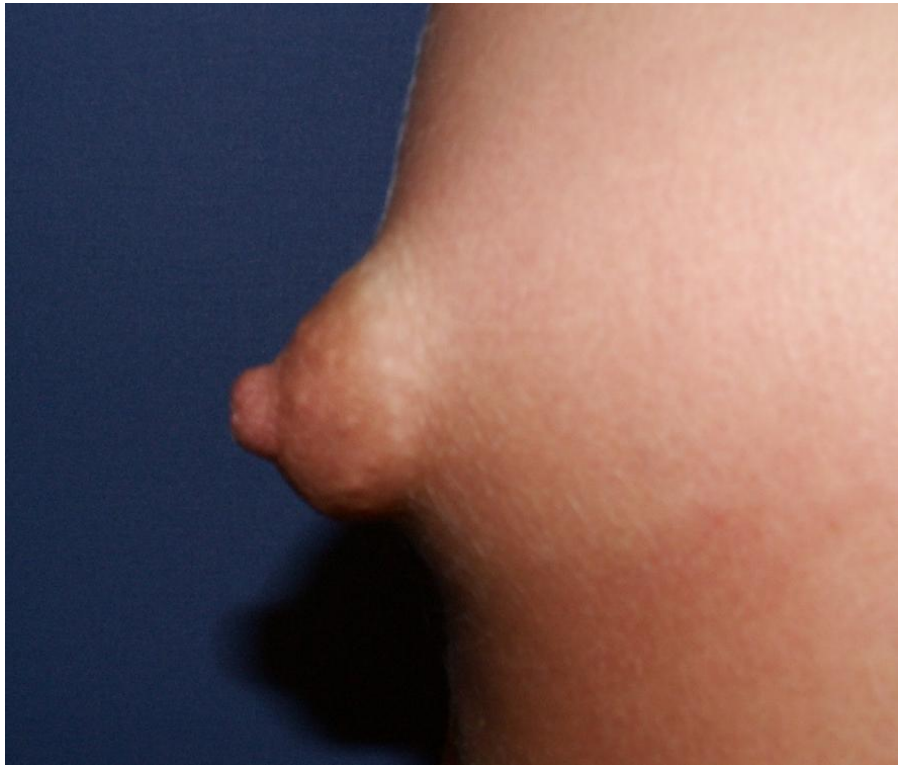

LES SEINS TUBÉREUX : UNE MISE AU POINT

C. Denoël (1), L. Soubirac (2), R. Lopez (3), J.L. Grolleau (3), J.P. Chavoin (4)

Rev Med Liege 2002; 57 : 10 : 655-660

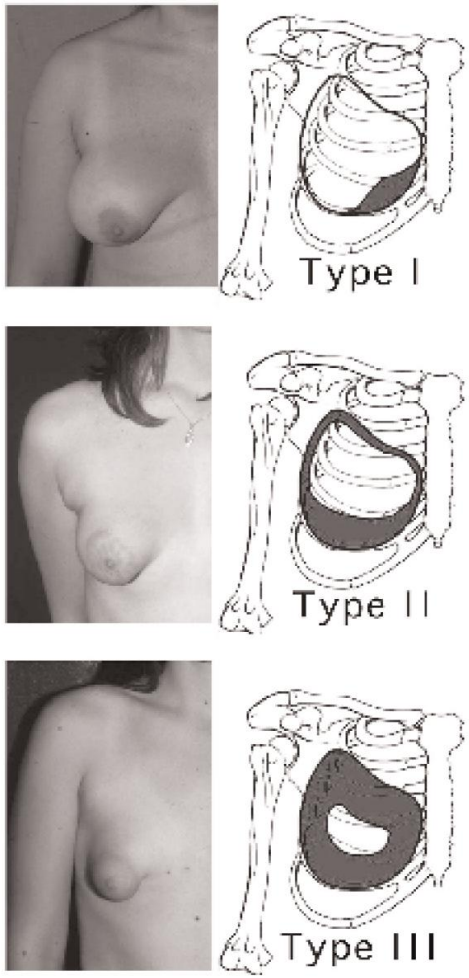

Fig. 2. Classification des seins tubéreux. A. Grade I. B.Grade II. C. Grade III.

- Grades I (56 %) : le segment inféro-interne est seul déficient. L'aréole regarde en bas et en dedans, mais le sein n'est pas toujours hypotrophique. Dans ce cas, un aspect en S italique de la portion inféro-interne du sein confirme sa nature tubéreuse.
- Grade II (26 %) : les deux segments inférieurs sont déficients. L'aréole regarde vers le bas.
- Grade III (18 %) : les segments inférieurs et supérieurs sont déficients. Le sein à base rétrécie prend l'aspect d'un tubercule.

Moderne Brustchirurgie: Von der Ästhetik bis zur Rekonstruktion

Rees and Aston (1976) telescoping technique for herniated nipple deformity. *A*, New nipple size and skin incisions are outlined. *B*, Breast tissue is denuded in the subcutaneous plane. *C*, Prostheses are placed under breast tissue on the prepectoral fascia. *D* and *E*, Breast tissue is telescoped into the new skin brassiere and the incisions are sutured. (From Rees, T. D., Aston, S. J.: The tuberous breast. Clin. Plast. Surg. 3:339, 1976.)

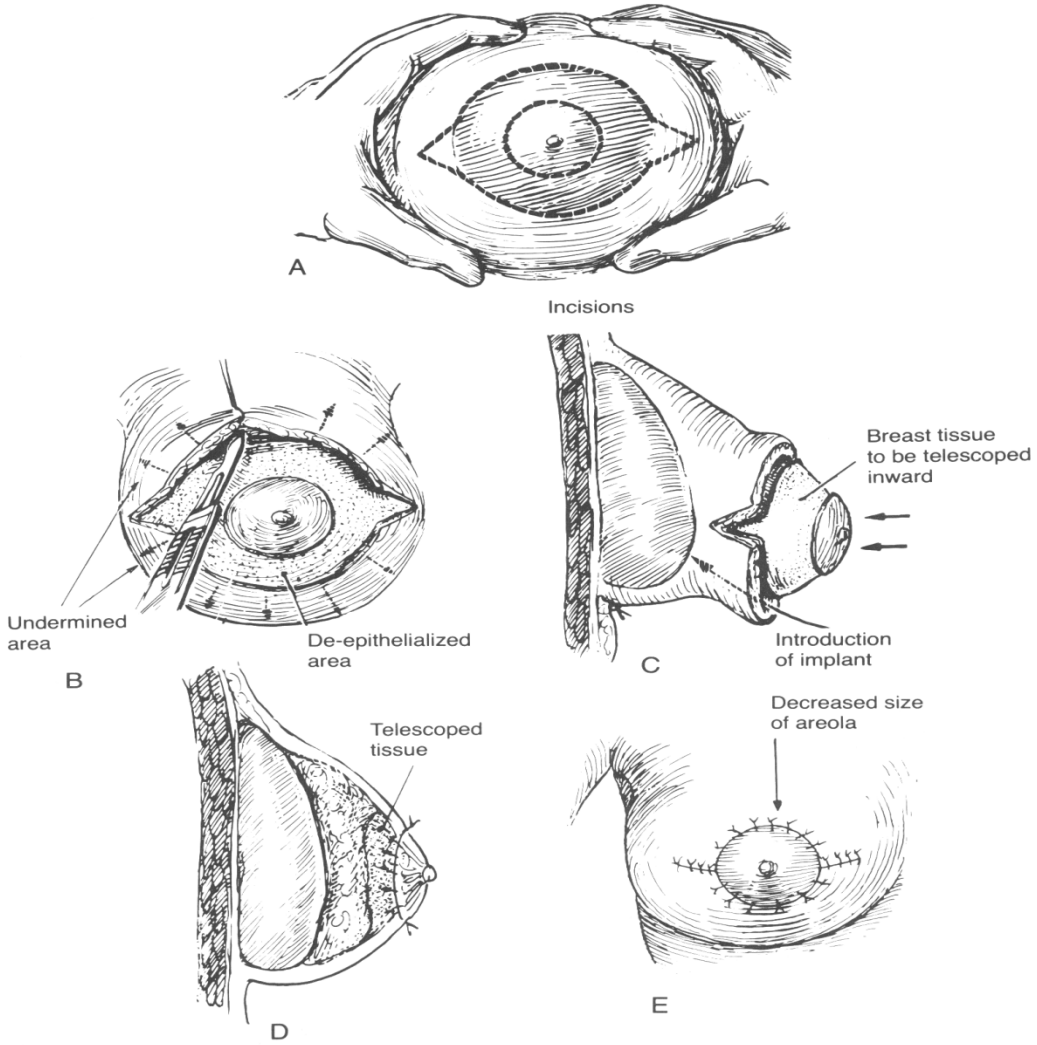

Vivantes

Moderne Brustchirurgie: Von der Ästhetik bis zur Rekonstruktion

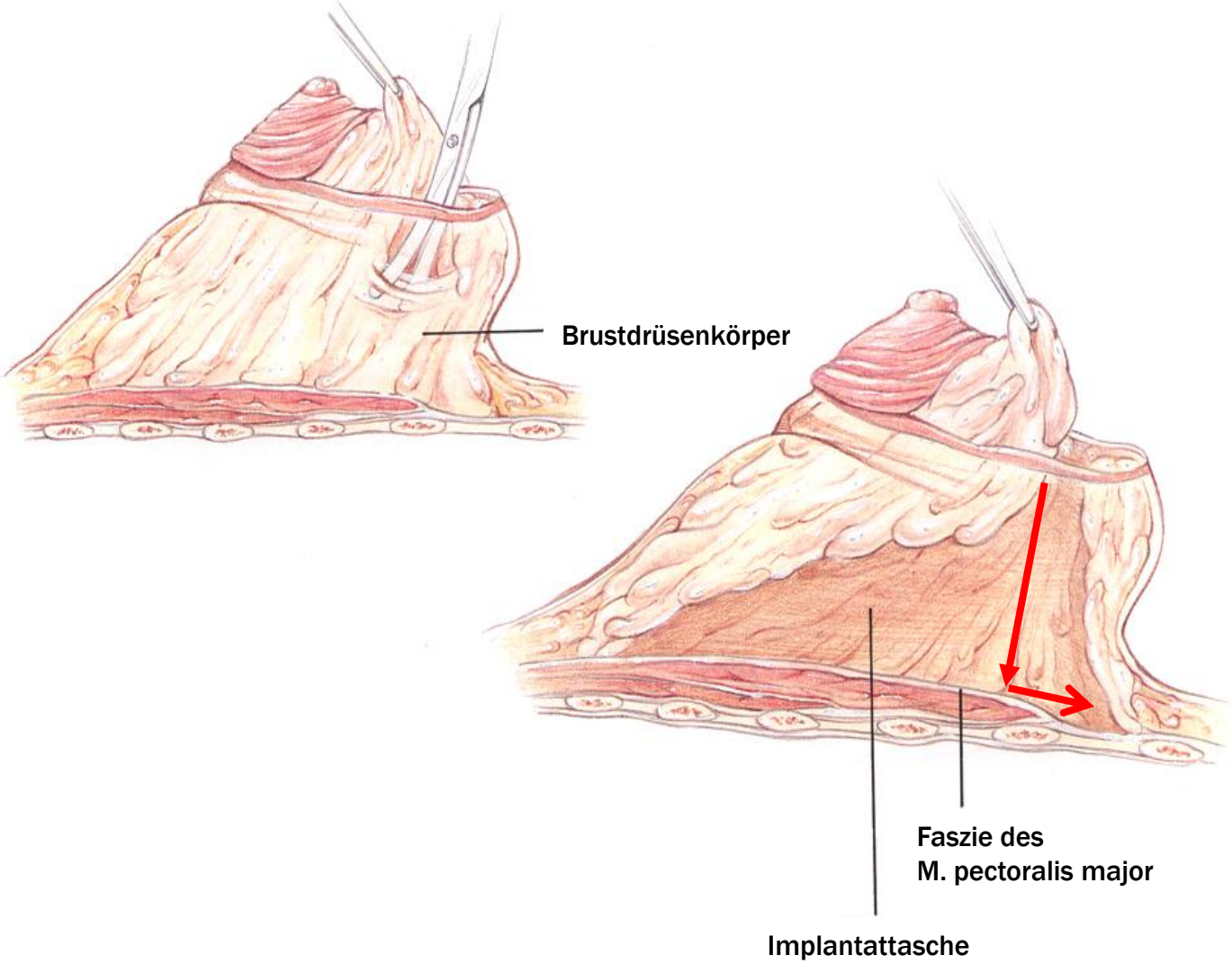

Vivantes

Moderne Brustchirurgie: Von der Ästhetik bis zur Rekonstruktion

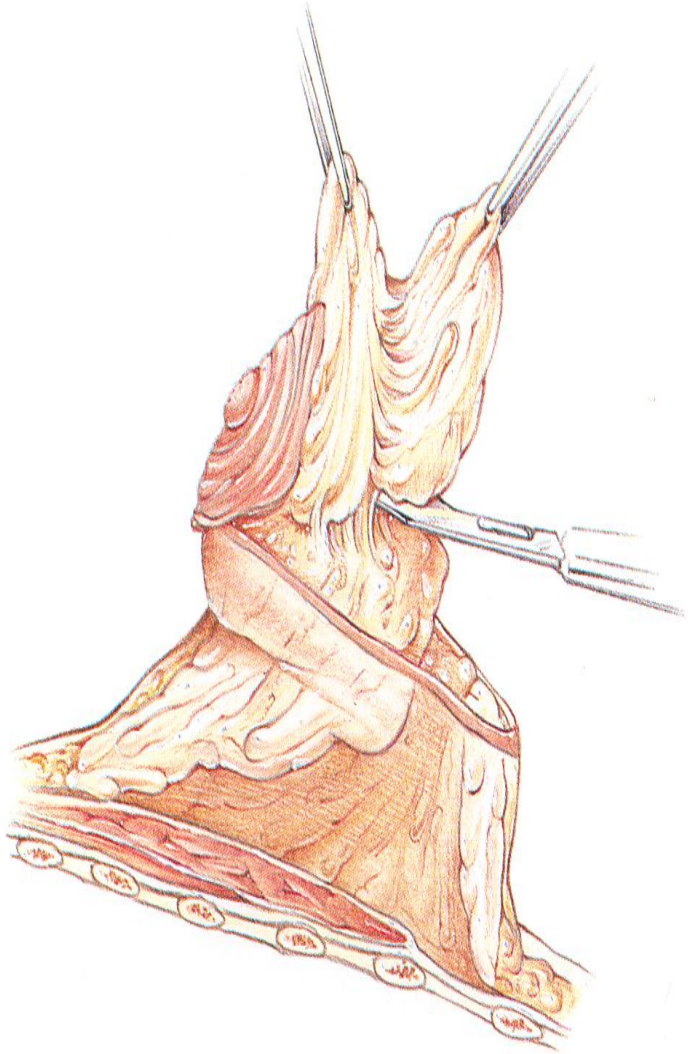

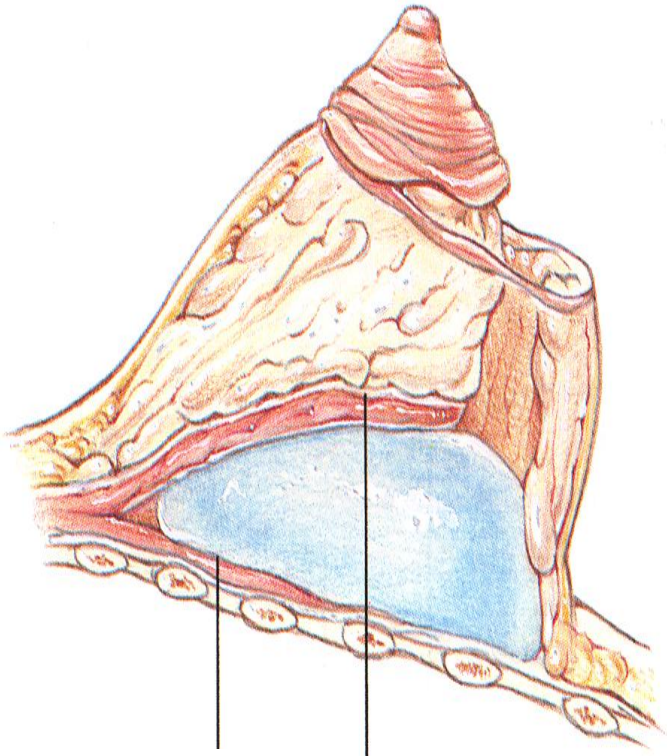

Implantat liegt
hinter dem
M. pectoralis major

Vivantes

Moderne Brustchirurgie: Von der Ästhetik bis zur Rekonstruktion

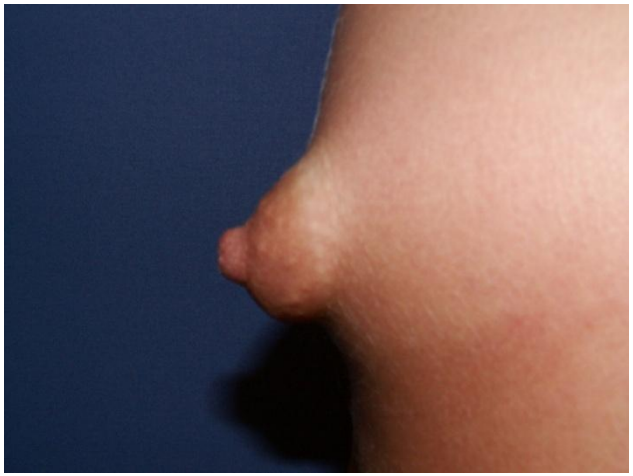

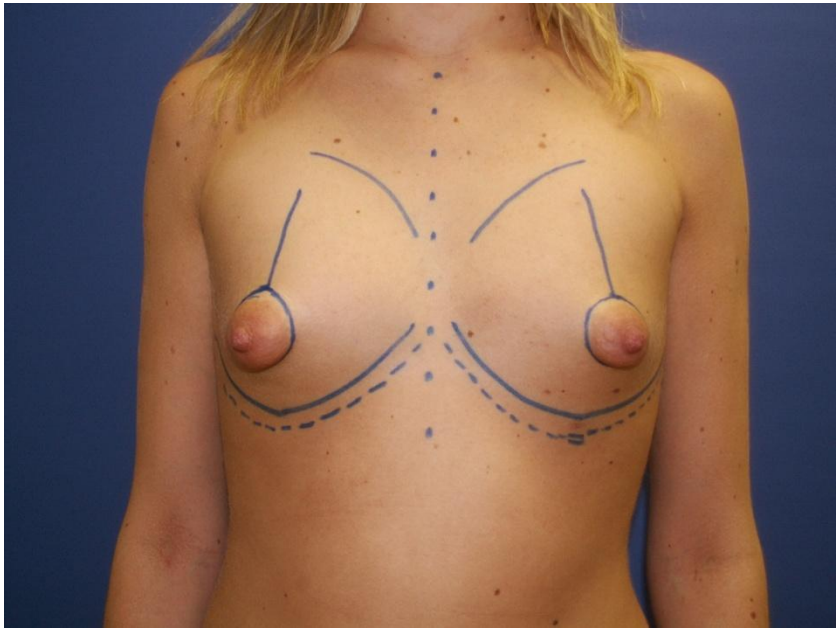

Vivantes

Komplikationen

Kapselfibrose
Infektion
Ruptur
Asymmetrie
Dislokation
Hämatom
Serom

Arch Gynecol Obstet (2005) 273: 79–85
DOI 10.1007/s00404-005-0026-x

ORIGINAL ARTICLE

Wulf Siggelkow · Antje Lebrecht · Heinz Kölbl
Andre Faridi

Dual-plane implant positioning for capsular contracture of the breast in combination with mastopexy

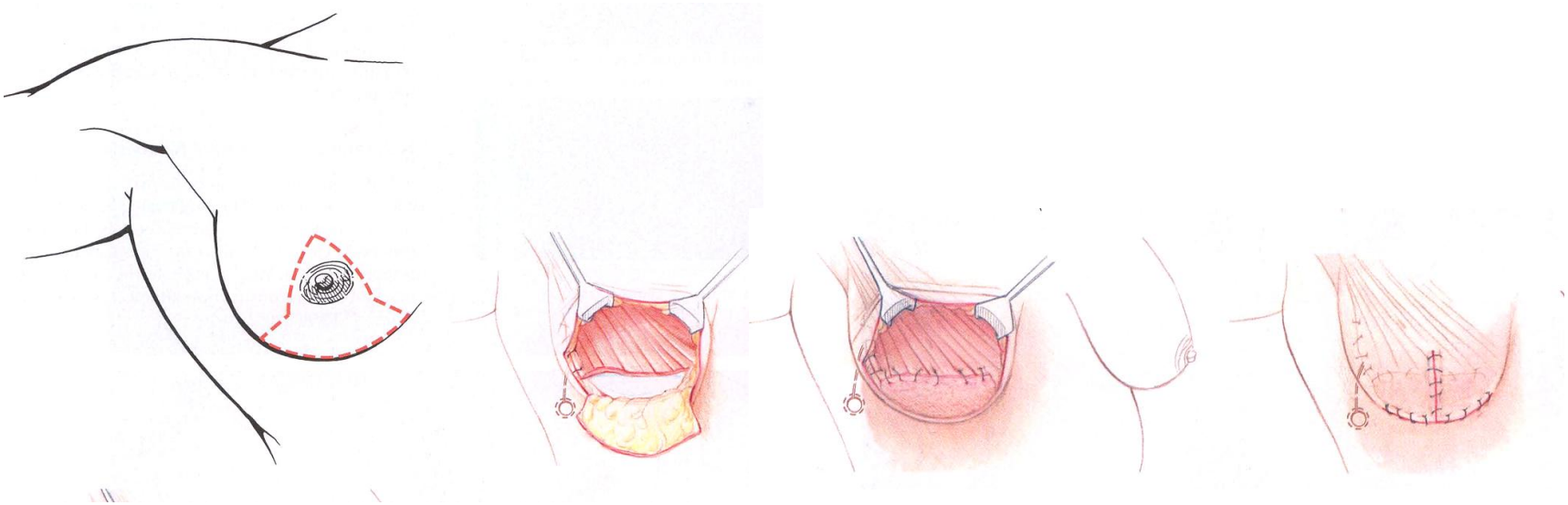

Vivantes

Moderne Brustchirurgie: Von der Ästhetik bis zur Rekonstruktion

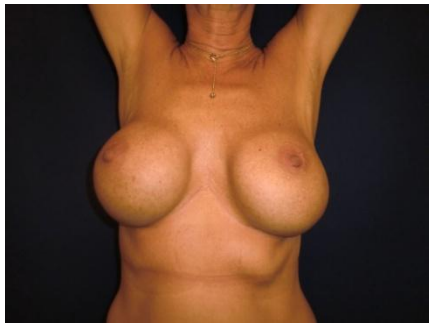

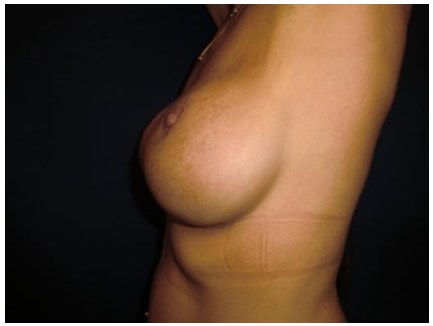

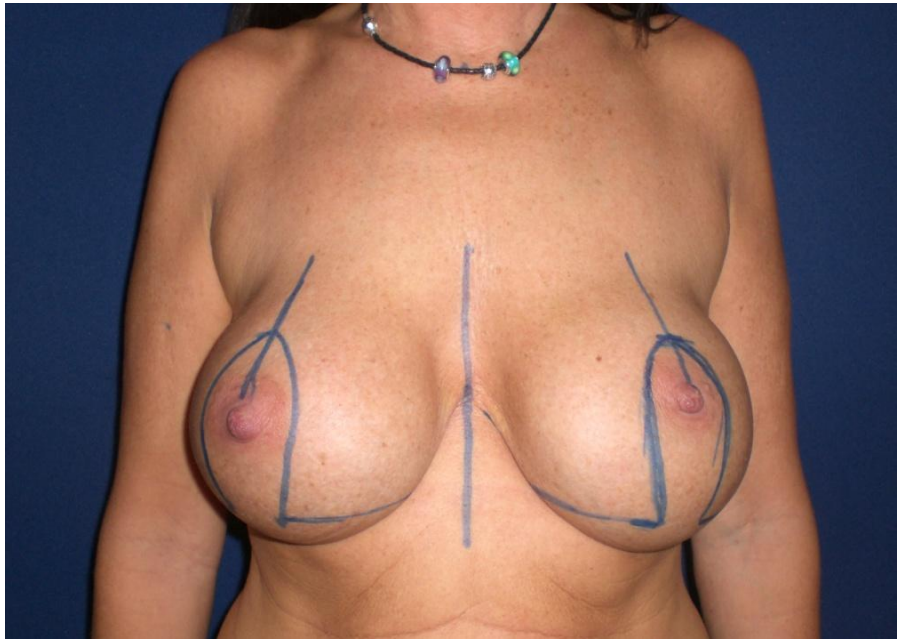

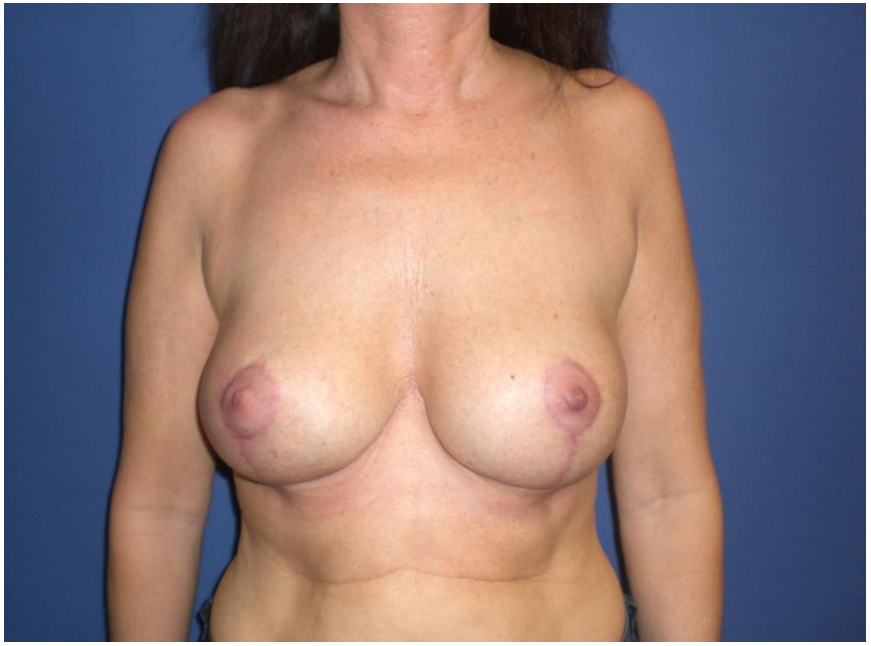

Vivantes

Arch Gynecol Obstet (2005) 273: 79–85
DOI 10.1007/s00404-005-0026-x

ORIGINAL ARTICLE

Wulf Siggelkow · Antje Lebrecht · Heinz Kölbl
Andre Faridi

Dual-plane implant positioning for capsular contracture of the breast in combination with mastopexy

Es geht auch ohne Implantat und Netz …

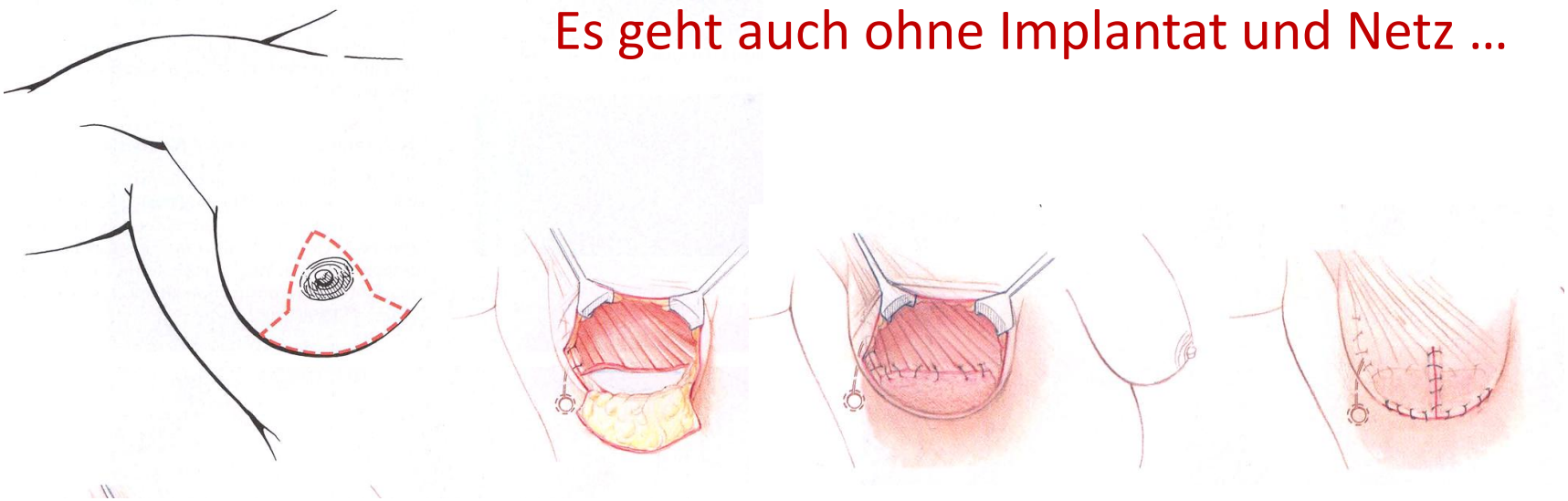

Vivantes

Moderne Brustchirurgie:

2002 subpectorale Augmentation bds.
2009 Implantat- und Kapselentfernung bds.
Hautreduktionsmastopexie mit inferiorem Dermofettlappen

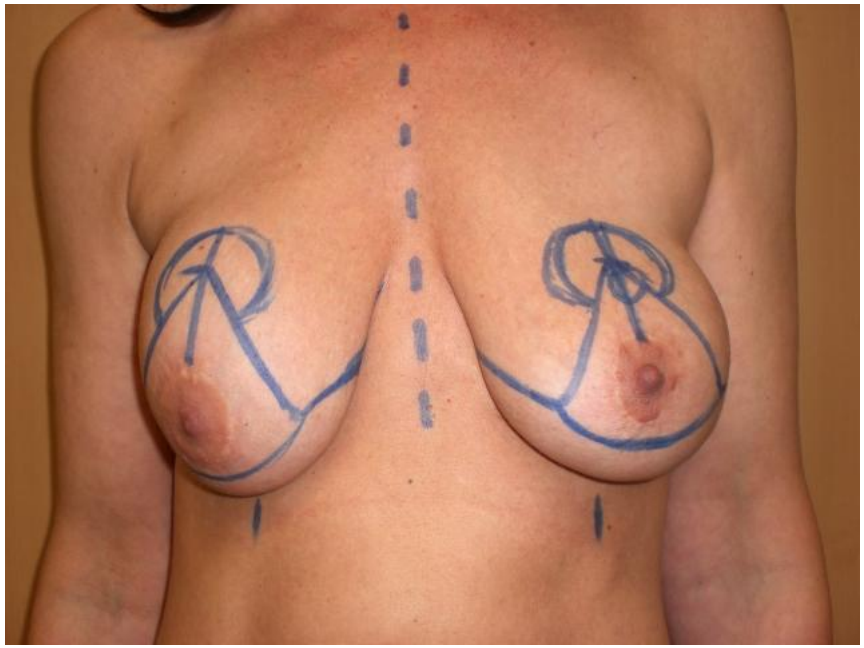

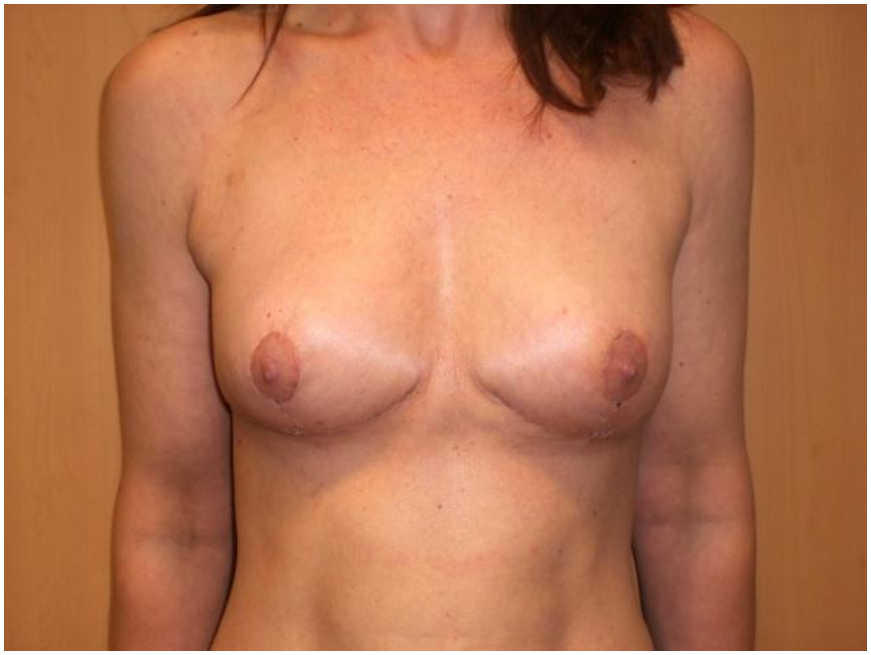

Vivantes

Moderne Brustchirurgie: Transsexualität

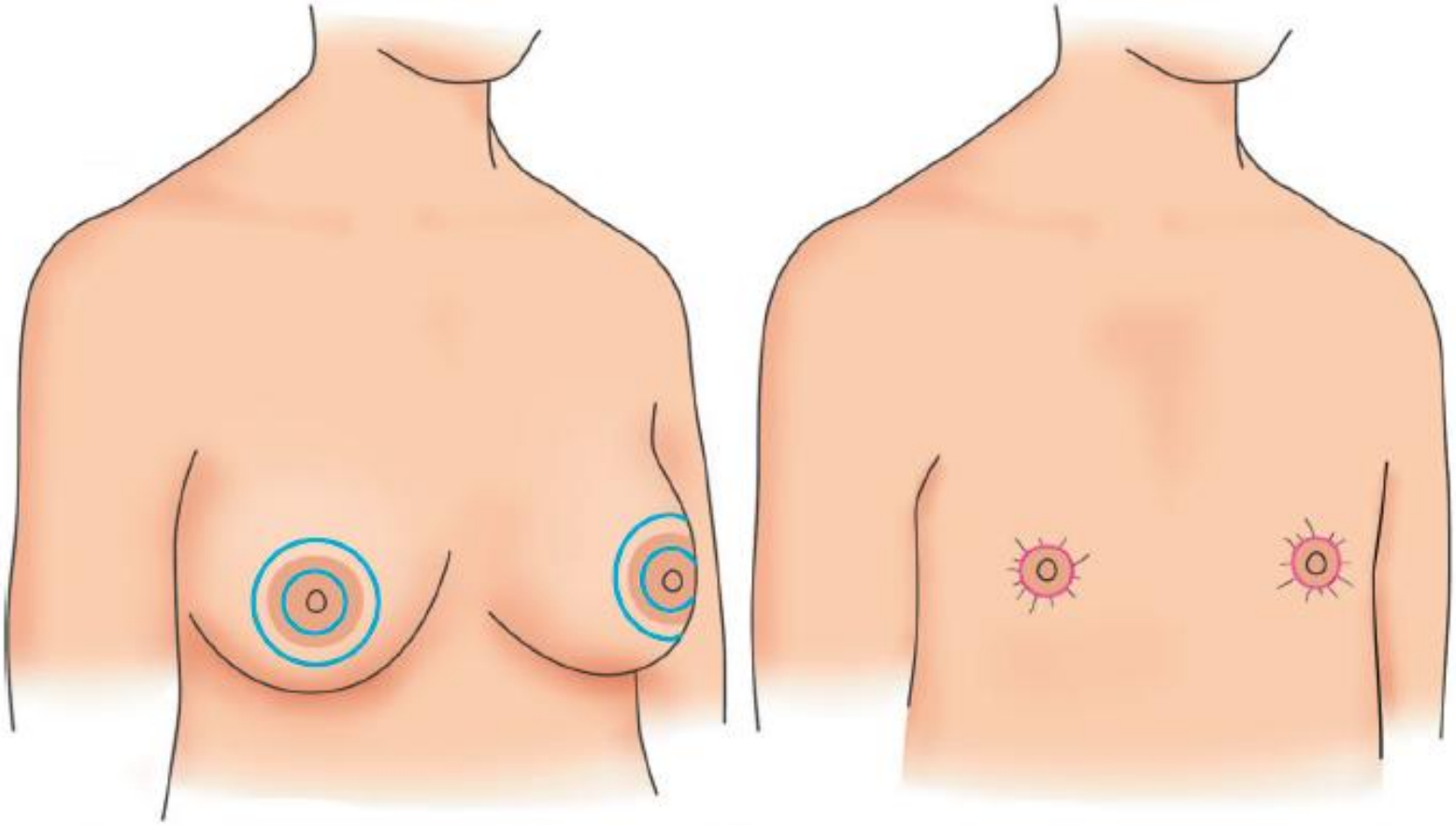

Vivantes

Moderne Brustchirurgie: Transsexualität

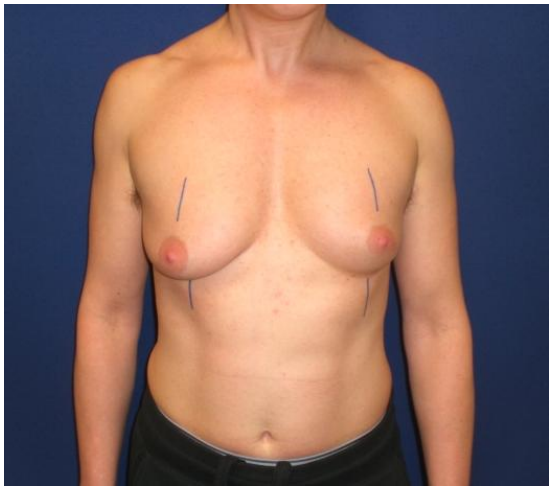
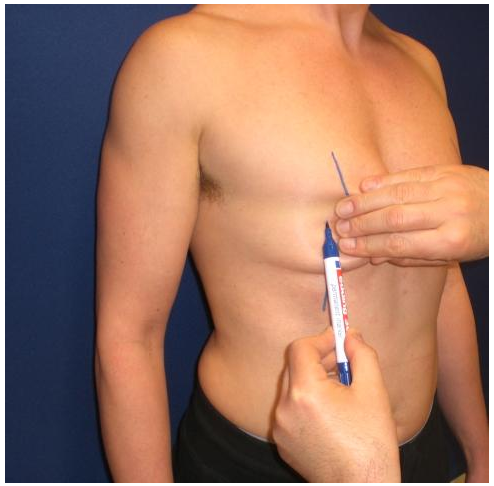
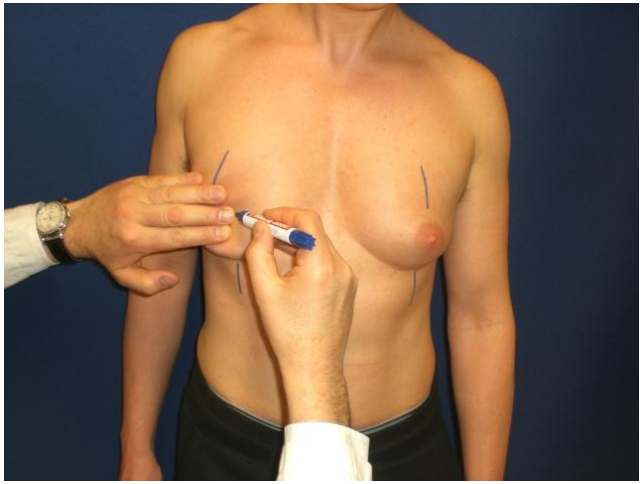
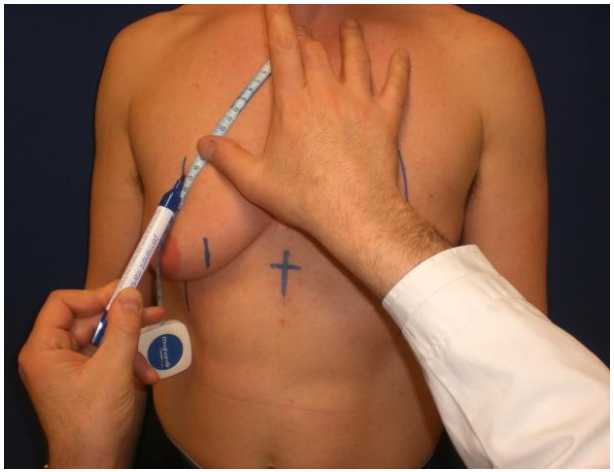
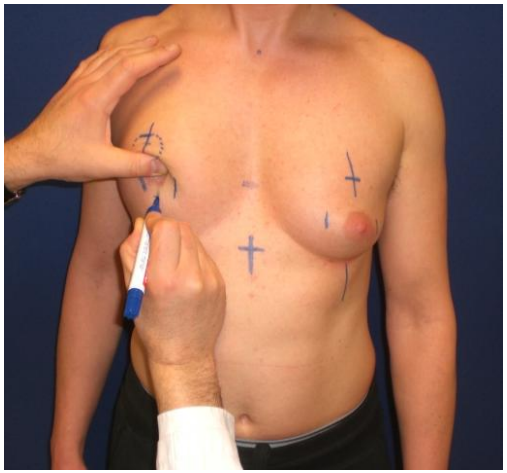
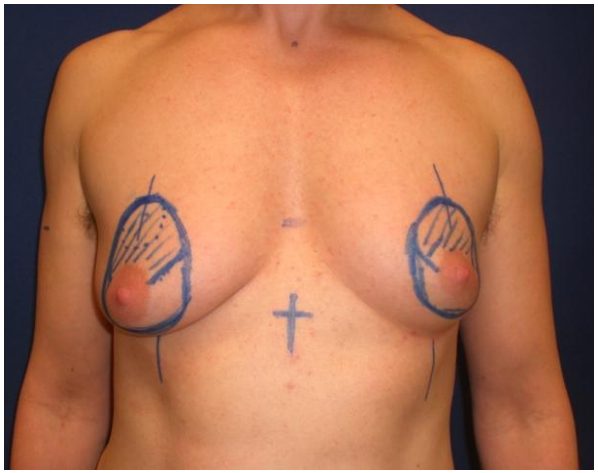

Vivantes

Moderne Brustchirurgie: Transsexualität

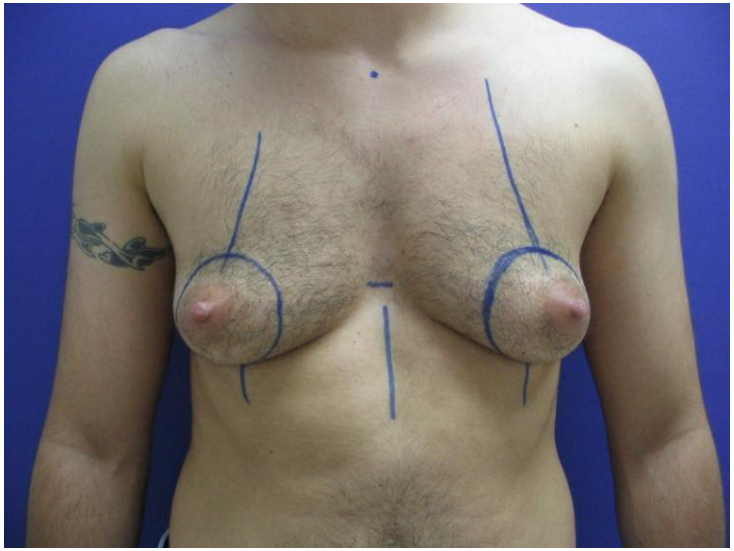

Moderne Brustchirurgie: Transsexualität

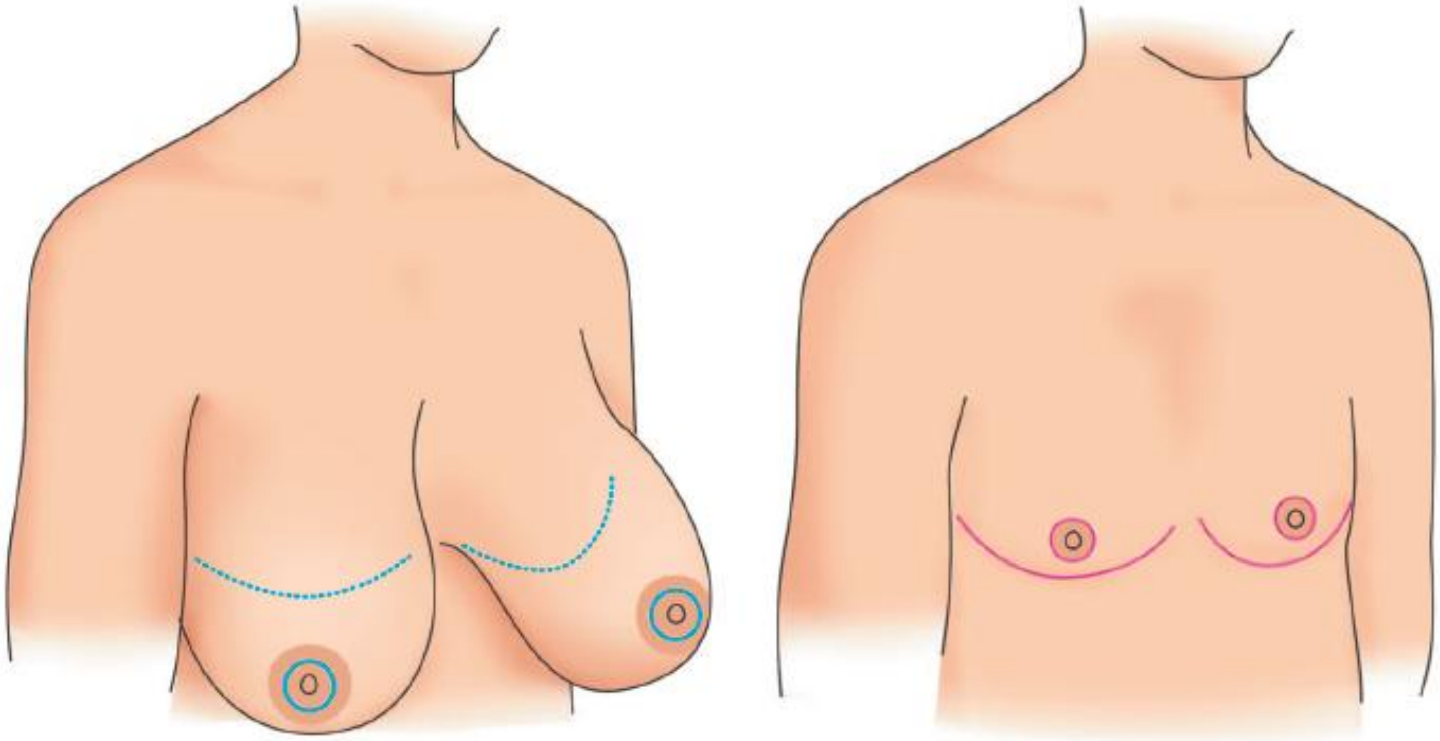

Monstrey S. Chest-Wall Contouring Surgery in Female-to-Male Transsexuals: A New Algorithm. Plast. Reconstr. Surg. 121: 849, 2008

Moderne Brustchirurgie: Transsexualität

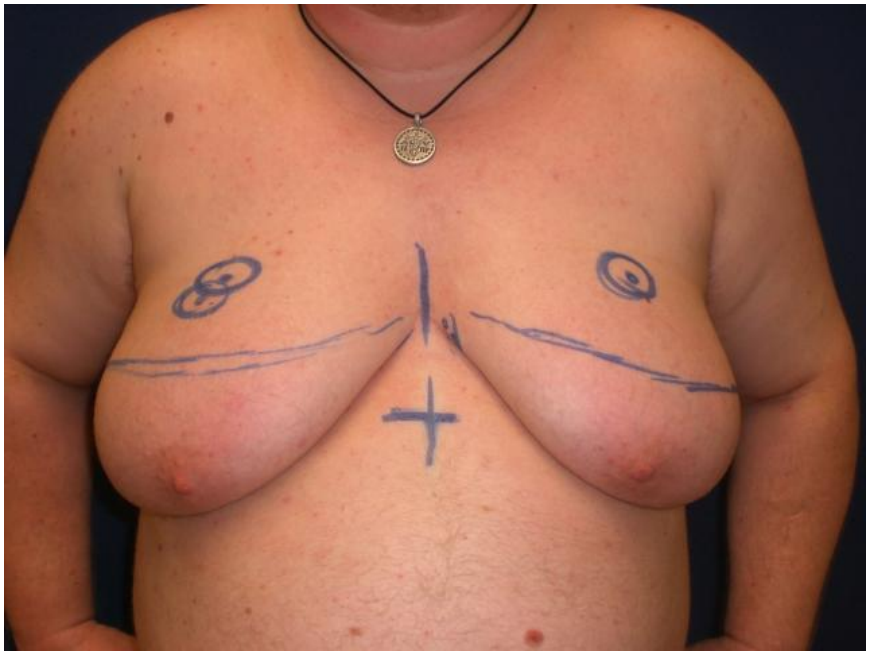

Vivantes

Vielen Dank für Ihre Aufmerksamkeit!

Vivantes